

Case report

POST TRAUMATIC ANTRAL STENOSIS IN A CAT

PELLONI Angelo¹, DEL SIGNORE Francesca^{2*}, ASTE Giovanni²,
ZORDAN Silvia¹, DE MAGISTRIS Angela¹, SIMEONI Francesco²,
PRAINO Domenico¹, BERTONCELLO Diana¹, VIGNOLI Massimo²

¹Veterinary Hospital I Portoni Rossi, Zola Pedrosa, Bologna, Italy; ²Veterinary Teaching Hospital, Faculty of Veterinary Medicine, University of Teramo, Italy

(Received 02. October 2018, Accepted 18. February 2019)

The goal of this study was to report the first case of antral stenosis in a cat. We have described a clinical case of a 9 months old domestic shorthaired cat referred for persistent and refractory vomiting, anorexia and loss of weight. Ultrasound (US) examination detected a mild gastric distension, mild wall thickening (5mm), severe serosal irregularities and a constriction between the fundus and body. Computed tomography (CT) was then performed: a severe gastric stenosis between the body and antrum with minimum contrast transit was detected and confirmed by flexible endoscopic examination. The antral localization of the stenosis was revealed after a cranial celiotomy and Y-U plastic was necessary to correct the defect. The patient completely recovered after surgery with significant body weight gain and remained in remission throughout a 2-years follow-up. While in human medicine there is evidence of acquired antral stenosis, no information is available about the same lesion in the feline species. To the best of our knowledge, this is the first case of antral stenosis in cats.

Keywords: antral, cat, CT, endoscopy, stenosis, US.

INTRODUCTION

The feline stomach is divided into the cardia, fundus, body and the distal third of the stomach, the pylorus. The pyloric portion can be further subdivided into the pyloric antrum and the pyloric canal [1]. Stenosis localized in the gastric antrum has never been described in cats, either due to congenital abnormalities or acquired diseases. This study aims to report a case of post-traumatic antral stenosis in a cat. The localization of the pathology of the anatomical area involved is singular; the difficulty encountered in issuing a definitive diagnosis of stenosis made necessary to deploy different imaging techniques.

*Corresponding author: e-mail: fdelsignore@unite.it

CASE PRESENTATION

A 9 months old domestic shorthaired cat was referred because of persistent and refractory vomiting, anorexia and loss of weight. The patient was successfully treated for a left pneumothorax after a presumptive road traffic accident twenty days before, and an abdominal ultrasound (US) performed on that occasion detected a gaseous infiltration of the wall of the stomach (Figure 1). Vomiting and anorexia occurred immediately after resolution of the pneumothorax and, despite several days of supportive therapy with gastro-protective, prokinetic and antiemetic therapy, vomiting got progressively worse. The cat was hospitalized and abdominal US was performed with an Esaote MyLab 70 XVG machine; the gastric fundus appeared mildly distended by food, its wall was mildly thickened (5 mm) with severe serosal irregularities, and a constriction between the fundus and body was detected. To better characterize the abnormalities, plain computed tomography (CT) was performed, followed by upper G-I CT with Iopamidol (Iopamiro®, Bracco Imaging S.p.A., Milan, Italy), administered via a gastric tube at a dose of 10 ml/kg, diluted 50% with water, and finally post contrast CT with the same contrast medium, 600 mg/kg, intravenously. A severe gastric stenosis between the body and antrum with minimum contrast transit was detected (Figure 2-3) and confirmed by flexible endoscopic examination with a Stortz 60814 PKL machine (Figure 4) performed after the CT examination. The antral localization of the stenosis was revealed after a cranial celiotomy and Y-U plastic was necessary to correct the defect (Figure 5). A jejunal tube was placed with a jejunostomy to allow the patient forced feeding, a jejunal pexis to the right side of the abdominal wall was performed by the surgeon. Because of the likely post-traumatic event, and the absence of gross malignancy signs during the surgery, no samples were collected for further histologic analysis. Twelve days after surgery, the jejunal tube and surgical stitches were removed. The patient completely recovered, with significant body weight gain and remained in remission throughout a 2-years follow-up.

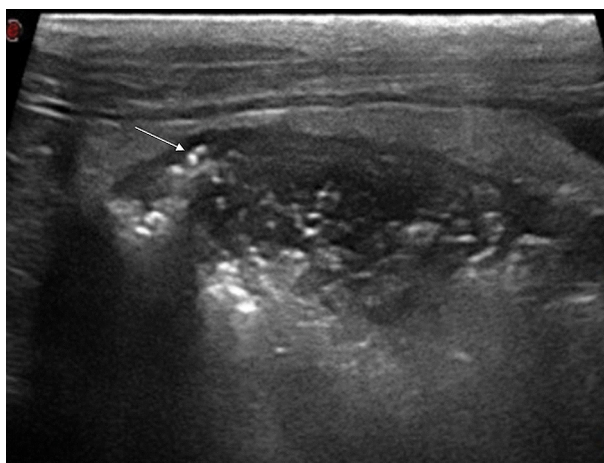


Figure 1. US image of the gastric fundus: notice the gaseous infiltration of the wall (white arrow)

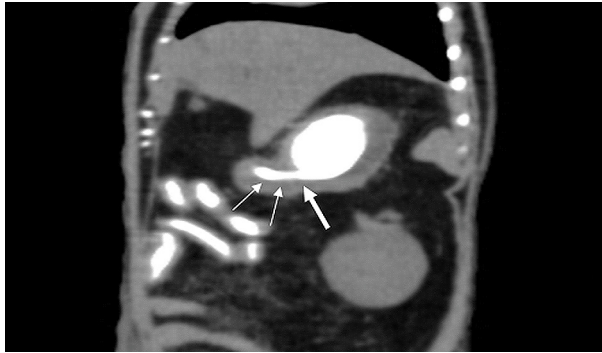


Figure 2. Image of post contrast CT: stricture at the body-antrum level is visible (thick white arrow); notice the transit reduction of the contrast media in the antrum (thin white arrows)

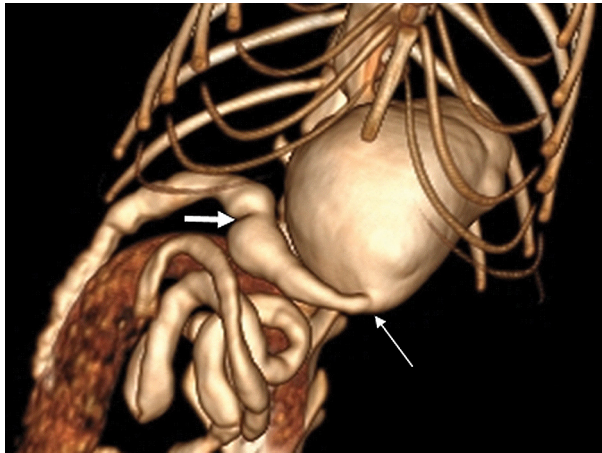


Figure 3. CT volume rendering of the stomach shows the severe antral stricture (white thin arrow); the white thick arrow points to the pylorus.

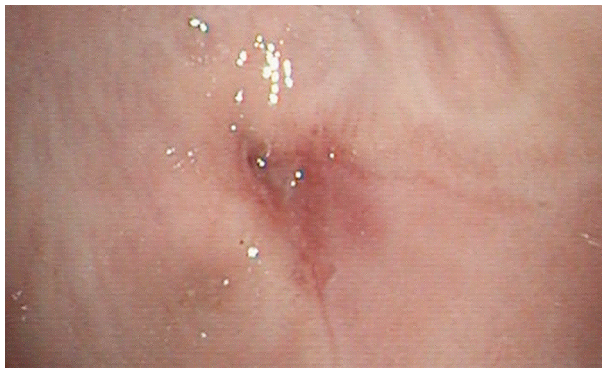


Figure 4. Endoscopic image of the antral stricture

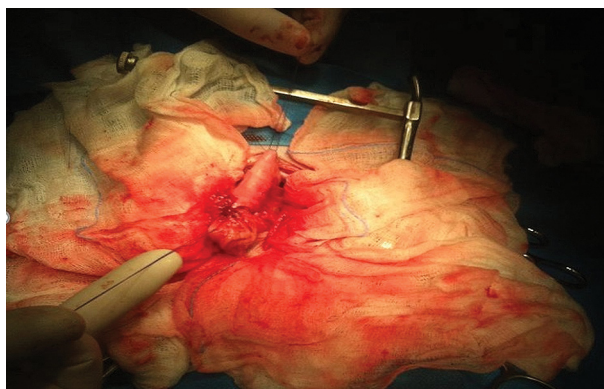


Figure 5. Image after the suture of the Y-U gastroplasty

Informed consent

Informed written consent was obtained from the owner of the cat included in the study.

DISCUSSION

In human medicine, acquired stenotic processes can be localized in the antral region as a result of many conditions. Advanced adenocarcinoma of the antropyloric region frequently determines a condition of gastric outlet obstruction (GOO), which requires treatment because of disastrous consequences that will supervene if the obstruction is not resolved [2]. Endoscopic submucosal dissection (ESD) was developed to enable en bloc resection of gastric neoplasms irrespective of size or ulceration within the lesion, resulting in a precise histological assessment of the resected specimen and reducing the risk of local recurrence. One of the complications of this technique is the post-operative onset of cicatricial processes that cause antral stenosis [2].

Another cause of acquired stricture in this area is the ingestion of caustic agents: this condition often causes severe corrosive gastritis, and the antrum is the main site of corrosive injuries to the stomach. The reasons why caustic agents mostly damage this portion of the stomach are their quick passage through the proximal stomach, with limited contact in this area, and prepyloric spasm, causing retention of the agent in the antrum. When destruction involves deep structures including muscular layers and injured tissue is replaced by dense fibrotic scar tissue, a stricture is likely to develop several weeks after ingestion [3,4]. In feline medicine few information are available about stenotic processes localized in the stomach. In Siamese cats benign muscular pyloric hypertrophy has been detected and, because of the young ages of cats in the reported cases and apparent heritability of the condition, a congenital etiology has been assumed [5,6]. No information is yet available about acquired antral stenosis. In our case we hypothesize that the stenosis was traumatic in nature because of the

absence of clinical signs prior to the traumatic event. The combination of different imaging modalities was necessary to achieve the correct diagnosis and define an adequate treatment plan, with ultrasound and post-contrast CT being very useful in diagnosing this unusual condition, later confirmed by endoscopy. To the best of our knowledge, this is the first case report describing a post-traumatic antral stenosis in a cat.

Ethical statement

All procedures have been executed in accordance with the Regulations on Animal Welfare in Veterinary Practice.

Authors' contributions:

PA, AG, ZS, DMA, PD, BD and MV actively participated in clinical, diagnostic and surgical procedures of this clinical case. DSF, MV, ZS, AG, DMA and SF participated in writing this manuscript. All authors have approved the final version of the manuscript.

Declaration of conflicting interests:

The author(s) declared no potential conflicts of interest with respect to the research, authorship, and/or publication of this article.

Statement of Informed Consent

The owner understood procedure and agrees that results related to investigation or treatment of their companion animals could be published in this journal.

REFERENCES

1. Barone R: Anatomia comparata degli animali domestici. Edagricole, Milano; 2006, Vol.3, 257.
2. Fiori E, Lamazza A, De Masi E, De Cesare A, Schillaci A, Sterpetti AV: Endoscopic stenting for gastric outlet obstruction in patients with unresectable antro pyloric cancer. Systematic review of the literature and final results of a prospective study. The point of view of a surgical group. *Am J Surg* 2013, 206:210-217.
3. Kamijo Y, Kondo I, Watanabe M, Kan'o T, Ide A, Soma K: Gastric Stenosis In Severe Corrosive Gastritis: Prognostic Evaluation By Endoscopic Ultrasonography. *Clin Toxicol* 2007, 45:284–286.
4. Gupta V, Wig JD, Kochhar R, Sinha SK, Nagi B, Doley RP, Gupta R, Yadav TD: Surgical management of gastric cicatrization resulting from corrosive ingestion. *Int J Surg* 2009, 7:257–261.

5. Syrcle JA, Gambino JM, Kimberlin WW: Treatment of pyloric stenosis in a cat via pylorotomy and gastroduodenostomy (Billroth I procedure). *J Am Vet Med Assoc* 2013, 15;242(6):792-7.
6. Nelson RW, Couto CG: (2014) *Small animal internal medicine* 5th edn. Elsevier, New York; 2014, 445

POSTTRAUMATSKA ANTRALNA STENOZA KOD MAČKE

PELLONI Angelo, DEL SIGNORE Francesca, ASTE Giovanni, ZORDAN Silvia, DE MAGISTRIS Angela, SIMEONI Francesco, PRAINO Domenico, BERTONCELLO Diana, VIGNOLI Massimo

Cilj studije je bio da se prikaže prvi slučaj antralne stenozе kod mačke. Opisan je klinički slučaj kod 9 meseci stare mačke, rase domaća kratkodlaka pri čemu je životinja imala stalni i refraktarni vomitus, anoreksiju i gubitak telesne mase. Ultrazvučnom metodom ispitivanja (US), uočena je blaga distenzija želudca, blago zadebljanje zida želudca (5 mm), izražene promene u serozi i konstrikcija između fundusa i tela želudca. Metodom kompjuterske tomografije (CT) uočena je izražena gastična stenozа između tela želudca i atrijuma, sa minimalnim prolaskom kontrasta što je potvrđeno ispitivanjem pomoću fleksibilne endoskopije. Antralna lokalizacije stenozе je dokazana na osnovu kranijalne celiotomije pa je bilo neophodno da se obavi Y-U plastika, sa ciljem korekcije promene. Pacijent se u potpunosti oporavio posle hirurškog zahvata uz značajno povećanje telesne mase uz ostajanje u stanju remisije u periodu posmatranja, naredne dve godine. Kod ljudi postoje podaci o nastanku stečene antralne stenozе, međutim nema podataka o ovom poremećaju kod mačaka. Prema našem saznanju, ovo je prvi slučaj antralne stenozе, opisan kod mačaka.