

POSTHODIPILOSTOMATOSIS IN A FISHPOND IN SERBIA

MARKOVIĆ MAJA*, ĆIRKOVIĆ M**, ALEKSIĆ NEVENKA*, MILOŠEVIĆ NIKOLINA**,
OLIVERA BJELIĆ-ČABRILLO***, DRAGANA LJUBOJEVIĆ**, AKSENTIJEVIĆ KSENIJA*
and RADOJIČIĆ MARINA*

*University of Belgrade, Faculty of Veterinary Medicine, Serbia

**University of Novi Sad, Faculty of Agriculture, Serbia

***University of Novi Sad, Faculty of Sciences, Serbia

(Received 22nd August 2011)

Posthodiplostomatosis (black spot disease) is a disease of young freshwater fish species of families Cyprinidae and Cobitidae, resulting from infection with metacercaria, which is the penultimate developmental stage of Posthodiplostomum cuticola. Metacercariae give rise to black cysts located primarily in the skin, muscles and on the fins. The disease caused by P. cuticola in certain fish species is first detected in a fishpond in Serbia, as presented in the current work, whilst in natural waters it has been existing for many years. Diagnosis of the infection in the grass carp (Ctenopharyngodon idella) and the bighead carp (Aristichthys nobilis) was based on the occurrence of dark discolorations and cysts of the parasite on the fins. Cysts measured approximately 1 mm in diameter, were confirmed by histopathological means.

Posthodiplostomatosis occurred in fishponds in which preventive measures were not implemented, i.e. where the nurseries were not dried up and mechanically cleaned.

Key words: black spots, metacercariae, posthodiplostomatosis, Posthodiplostomum cuticola

INTRODUCTION

Posthodiplostomatosis is a disease occurring primarily in fish species of the Cyprinidae and Cobitidae families living in fresh waters (Sonin, 1986). It has been most frequently described in the freshwater bream (*Abramis brama*), rudd (*Scardinius erythrophthalmus*), common roach (*Rutilus rutilus*) (Rakauskas and Blazevicius, 2005), ide (*Leuciscus idus*), the white bream (*Blicca bjoerkna*) (Soylu, 2006), Prussian carp, *Carassius gibelio*, (Shukerova, 2005).

The infection is known worldwide, in Euroasia: Croatia (Zrnčić *et al.*, 2009), Czech Republic (Ondracková *et al.*, 2002; 2004; 2006; Faltynková, 2005), Poland (Dzika, 2002; Popiolek and Kotusz, 2003; Mierzerjewska 2004; Rolbiecki, 2004; 2006; Dzika *et al.*, 2008), Germany (Schuster, 2001), Lithuania (Rakauskas and

Blazevicius, 2009), Russia (Kurochkin and Biserova, 1996), Finland (Koie, 1999), Bulgaria (Shukerova, 2005), FYRM (Baker *et al.*, 2004), Turkey (Ozturk, 2005; Soylu, 2006), and has also been described in fish species in subtropical streams in Uruguay (Teixeira-de Mello and Eguren, 2008).

Being an allogenic species, *Posthodiplostomum spathaceum* (Digenea: Diplostomatidae, Nordmann, 1832), the causative agent of this trematode infection requires two intermediate hosts, a snail of *Planorbis* genus and cyprinide fish, whilst the definitive host is one of the numerous wading bird species, for example the grey heron (*Ardea cinerea*) or other species of the genus (Donges, 1964; Moravec *et al.*, 1991). Following feeding on infected fishes, in the birds' digestive systems reproduction of adult flukes takes place. The eggs are passed via excreta into the water where the released miracidia penetrate the snails and begin a new life cycle (Olsen, 1974; de Kinkelin *et al.*, 1985; Schaperclaus, 1990). Infection of fish leads to circumscribed dark spots the average size of the head of a sewing pin, occurring on the skin, fins and muscles (Lucky, 1970; Schaperclaus, 1990; Kurochkin and Biserova, 1996). *P. cuticola* has been reported as pathogenic for the fish host, being capable of producing lethality, especially during the first months of fish life (Lucky, 1970; Ondrackova *et al.*, 2004).

Infection of fishes occurs when furcocercariae penetrate the skin, and consequently transforming into metacercariae, invade predominantly the skin of the fins, abdomen and sometimes the gills. Infection is usually asymptomatic, but in fingerlings, or in cases of severe infection, may be deleterious.

The grass carp (*Ctenopharyngodon idella*) and bighead carp (*Aristichthys nobilis*) are herbivorous freshwater fishes. Given their delicious taste and high growth rate, they are cultured worldwide, as well as in Serbia. Infection of the species caused by *Posthodiplostomum cuticola* has not been noticed in fishponds in Serbia until now, being first described in the present work. However, it was described in freshwaters (Markovic and Krsmanovic, 2008).

MATERIAL AND METHODS

The investigation was carried out throughout 2008 and 2009 on a fish farm in Susek in Northern Serbia.

A total of 200 specimens of grass carp (*Ctenopharyngodon idella*) and the same number of bighead carp (*Aristichthys nobilis*) aged from eight to ten months were examined for the presence of parasites. The fishes were caught in square nets and kept alive in buckets of fresh water until transported to the laboratory. The specimens were killed humanely with sodium pentobarbital 80 mg/kg of body weight administered intra-abdominally. The skin and, following dissection, the internal organs of the fishes were scanned by stereomicroscope for the presence of encysted metacercariae of *Posthodiplostomum cuticola*.

Histological examination

Patohistological examination was performed by standard techniques: following fixation with Bouin's solution, the tissue samples were processed, sliced to 5- μ m-thick sections, mounted and stained in haematoxylin and eosine. The

diameters of 50 cysts originating from each fish species were measured in histological sections, with an ocular micrometre (Zeiss) at 40x and 100x magnifications.

Statistics

The condition of the hosts and parasitological indices (prevalence and mean intensity of infection) were observed. The distribution of metacercaria on the fishes was calculated and the existence of differences among body parts was checked with ANOVA. Fish bodies were virtually divided into five parts, similarly to what was done by Rolbiecky (2004): the head, oral cavity including the gills and the eye sockets, dorsal and ventral parts of the body (dorsal and ventral to the line determining the *longitudo caudalis*) and the fins. The data obtained were compared between the grass carp (*Ctenopharyngodon idella*) and bighead carp (*Aristichthys nobilis*).

RESULTS

Posthodiplostomosis was diagnosed on the fishfarm in Susek, located in the southwest of Vojvodina (45 13' 27"N, 19 31' 57"E).



Figure 1. Young grass carp (*Ctenopharyngodon idella*) with *Posthodiplostomum cuticola* infection

The disease was first diagnosed at the end of June in eight to ten-month old juvenile grass carps (*Ctenopharyngodon idella*) and simultaneously, in the bighead carp (*Aristichthys nobilis*), leading to dark spots on the skin and fins, visible to the naked eye (Figures 1, 2a and 2b). The average size of the spots varied from 900 μm to 980 μm in both species, being $946.5 \pm 25.19 \mu\text{m}$ on average in the grass carp and $944.5 \pm 23.50 \mu\text{m}$ in the bighead carp (Table 1). The size of metacercaria on the two species did not differ significantly ($p < 0.01$).




Figure 2a and Figure 2b. Metacercaria in the fin of the grass carp (*Ctenopharyngodon idella*) infected with posthodiplostomum

Table 1. Diametres of the cysts with *Posthodiplostomum spathaceum* metacercaria

Cysts	Fish species	
	Grass carp	Bighead carp
Size range	From 900 to 990 μm	From 900 to 980 μm
Mean \pm SD	946.5 \pm 25.19	944.5 \pm 23.50

The prevalence of the disease reached 100% in both species.

The diagnosis was confirmed by microscopic examination of suspected tissue samples identifying *P. cuticola* metacercaria surrounded by melanin deposits (Figures 3 and 4).

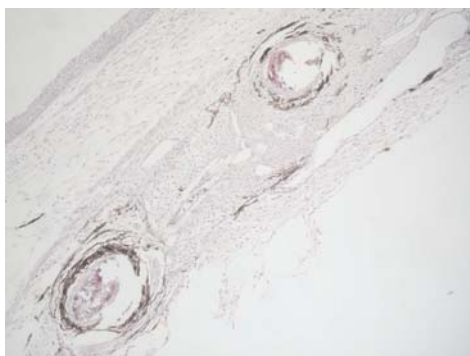


Figure 3. *Ctenopharyngodon idella*: transversal section of the fin infected with *Posthodiplostomum cuticola* metacercaria (HE, x200)

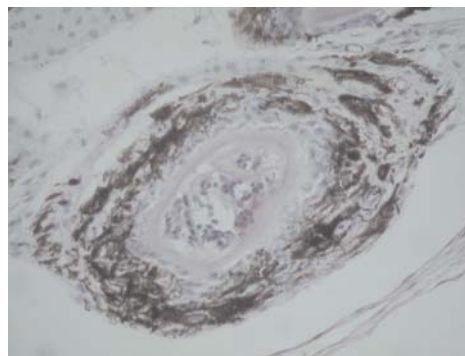


Figure 4. *Ctenopharyngodon idella*: *Posthodiplostomum cuticola* metacercaria with surrounding melanin deposits in the fin (HE, x400)

Following the examination of gross and/or microscopic changes in fishes, the total number and distribution of metacercaria in each specimen was counted and the average calculated (Table 2).

Table 2. Numbers of *Posthodiplostomum cuticola* metacercaria per fish

1	2	3	4
No of metacercariae per fish specimen	Grass carp <i>Ctenopharyngodon idella</i> (No)	Bighead carp <i>Aristichthys nobilis</i> (No)	Correlation coefficient (between 2 and 3)
1	55	67	0.993259
2	62	79	
3	17	14	
4	8	10	
5	5	6	
6	9	5	
7	8	8	
8	8	4	
9	3	6	
10	5	0	
11	4	0	
12	3	1	
13	5	0	
14	3	0	
15	3	0	
16	2	0	
Total fish number	200	200	

The number of metacercaria per fish ranged from one to sixteen, the latter found only in the grass carp (Table 2). Although the distribution seemed to vary, the correlation coefficient between the arrays describing the number of fishes infected with a certain number of metacercaria correlated highly (correlation coefficient $r=0.9933$). The largest numbers of both species were infected with one to two metacercaria.

The distribution of metacercaria in various fish body parts is on display in Table 3. The largest number was found on the fins, followed by the ventral parts of the body and the head, whilst the least was situated in the oral cavity including the gills and the eye sockets, and, finally, the lowest number was recorded on the dorsal body parts.

Table 3. Distribution of Posthodiplostomum metacercaria found on the grass carp and bighead carp

Body part	Grass carp (<i>Ctenopharyngodon idella</i>)		Bighead carp (<i>Aristichthys nobilis</i>)		Correlation coefficient (Pearson's r)
Head	49	3.097	58	4.758	0.9937
Oral cavity (including the gills and eye sockets)	54	3.413	19	1.559	
Dorsal parts of the body	196	12.389	97	7.957	
Ventral parts of the body	302	19.090	269	22.067	
Fins	981	62.010	776	63.659	
Total	1582	100	1219	100	

DISCUSSION

Posthodiplostomum cuticola is a trematode species introduced to fishponds from rivers by means of wading birds, the definitive host. There have been reports of its presence in free-living fishes in the region, but this is the first time that it is described in a fish farm in Serbia.

The trematode is reported to produce metacercaria preferably on the fish body surface. The metacercaria are located in cysts or, more precisely, black spots, approximately 1 mm in diameter. The average size of the cysts in the grass carp was $946.5 \pm 25.19 \mu\text{m}$, whilst in the bighead carp, being not much different: $944.5 \pm 23.50 \mu\text{m}$. The possible reason for the seemingly different size obtained in Susek is that a more precise method was used to estimate the diameter (ocular micrometre) and that it was performed on histological slices rather than on the fish body directly with a micrometre.

The metacercaria themselves are known to be smaller, being 0.73-0.92 mm long and 0.29-0.31 mm wide (Shukerova, 2005).

The intensity of infection in the grass carp (*Ctenopharyngodon idella*) and bighead carp (*Aristichthys nobilis*) ranged from one to sixteen, most frequently being lower. It was largely in accordance with the findings of Ondrackova (2002), who reported from 1.8 to 13.3 on average, in different fish species. On the other hand, Rakauskas and BlazeVICIUS (2009) described from 6.2 to 12.7 metacercaria per fish, whilst Shukerova (2005) only 0.39. Given that the intensity of infection was described on different fish species and not having been published for the grass carp (*Ctenopharyngodon idella*) and bighead carp (*Aristichthys nobilis*), and that it depends on numerous factors, it may be concluded that it is not readily comparable.

One of the factors of utmost importance which facilitates the presence of the disease is that on the fishpond Susek is impossible to dry nursery ponds and expose them to low temperatures. Thus, the overwintering of snail intermediate hosts is enabled. The inevitable measure in the eradication of

posthodiplostomatosis is the breaking of its developmental cycle, which is to be done by diminishing the population of the mollusc intermediate hosts rather than the avian one. In addition, treatment with hydrated lime (approximately 100 kg per 1000 m²) is the most efficient measure against most fish diseases including posthodiplostomatosis.

Another possible reason for the presence of *Posthodiplostomum cuticola* metacercaria in Susek is the lush macrophytic vegetation in the surrounding which seems ideal for nesting of herons and other bird species, potential definitive hosts to this digenean fluke.

Posthodiplostomatosis is one of the fish diseases which inflicts serious damage to fishes, mainly fingerlings. Certain investigations revealed that it possibly influences the weight gain in fishes (Marković and Krsmanović, 2008).

It may be concluded that more research should be conducted to cast light on the reason(s) why *Posthodiplostomum cuticola* is abundant in Susek but not in other fish farms in its vicinity. Given that its life cycle involves two intermediates (a fish and a snail) and a definitive host (wading birds), whose presence and abundance depend on various abiotic factors (Ondrackova et al., 2004), it is to be supposed that thorough investigations in the field are justifiable to get a reasonable answer to the question. Furthermore, following the completion of research on the parasites of the birds in the vicinity of the fish farm, it will be possible to implement appropriate measures for the control of parasites in fish.

Address for correspondence:
Dr. Maja Marković, Assistant professor
University of Belgrade
Faculty of Veterinary Medicine
Bulevar oslobođenja 18
11000 Belgrade, Serbia
E-mail: maja.markovic@vet.bg.ac.rs

REFERENCES

1. Baker RA, Hristovki N, Stojanovski S, 2004, Ecological aspects of the Macedonian lakes – Examples of international co-operation, *BALVOIS*.
2. Bartosova S, Jurajda P, Ondrackova M, 1999, Posthodiplostomosis of 0+ juvenile cyprinid fish, *Helminthologia*, 36, 123-36.
3. Dönges J, 1964, The life cycle of *Posthodiplostomum cuticola* (v. Nordmann 1832) Dubois 1936 (*Trematoda, Diplostomatidae*), *Z Parasitenk*, 24, 160-248.
4. Dzika E, 2005, Changes in the parasitic fauna of rudd *Scardinius erythrophthalmus* (L.) from Lake Warniak, Poland, *Helminthologia*, 42, 219-22.
5. Dzika E, Kusztala M, Kozłowski J, 2008, Metazoan parasite fauna of fish species in lake Kortowskie, *Arch Pol Fish*, 16, 75-86.
6. Faltynkova A, 2005, Larval trematodes (Digenea) in molluscs from small water bodies near České Budejovice, Czech Republic, *Acta Parasitol*, 50, 49-55.
7. Koie M, 1999, Metazoan parasites of flounder *Platichthys flesus* along the transect from the southwestern to the northeastern Baltic sea, *ICES J Marine Sci*, 56, 157-63.
8. Kurochkin IuV, Biserova LI, 1996, The etiology and diagnostics of 'black-spot disease' in fish, *Parazitologiya*, 30, 117-25.
9. Lucky Z, 1970, Pathological changes with posthodiplostomosis of fish fry, *Acta Vet Brno (Suppl)*, 1, 51-66.

10. Marković G, Krsmanović M, 2008, The influence of *Posthodiplostomum cuticola* (Digenea, Trematodes) metacercariae infestation on the growth rate of *Leuciscus cephalus* L. (Cyprinidae, Pisces), *Acta Agr Serbica*, 18, 73-6.
11. Mierzerjewska K, Wlasow T, Kapusta A, Szyranczyk K, 2004, Fish digeneans from the seven islands ornithological reserve at Oswin lake Poland. Part I. *Posthodiplostomum cuticola* von Nordmann, 1832, *Acta Ichthyol Piscat*, 34, 73-84.
12. Moravec F, Ergens T, Našincova V, Scholz T, 1991, Parasitic Metazoa. In: Svobodova Z, Vykusova B. (Eds) Diagnostic, prevention and therapy of fish diseases and intoxications, Research Institute of Fish Culture and Hydrobiology, Vodnany, Czechoslovakia.
13. Ondrackova M, Jurajda P, Gelnar M, 2002, The distribution of *Posthodiplostomum cuticola* metacercariae in young-of-the-year cyprinid fishes, *J Fish Biol*, 60, 1355-7.
14. Ondracková M, Šimková A, Gelnar M, Jurajda P, 2004, *Posthodiplostomum cuticola* (Digenea: Diplostomatidae) in intermediate fish hosts: factors contributing to the parasite infection and prey selection by the definitive bird host, *Parasitology*, 129, 761-70.
15. Ondrackova M, Davidova M, Gelnar M, Jurajda P, 2006, Susceptibility of Prussian carp infected by metacercariae of *Posthodiplostomum cuticola* (v. Nordmann, 1832) to first predation, *Ecol Res*, 21, 526-9.
16. Ozturk OM, 2005, An investigation on metazoan parasites in common carp (*Cyprinus carpio*) in lake Ebe, Afyon, Turkey, *Turkiye Parazitoloji Dergesi*, 29, 204-10.
17. Popiolek M, Kotus J, 2003, Endoparasitic helminths of fishes of the genus *Cobitis* from Poland. *Folia Biol-Krakow*, 51 (Suppl), 173-8.
18. Rakauskas V, Blazevicius C, 2009, Distribution, prevalence and intensity of roach (*Rutilus rutilus* Linnaeus, 1758) parasites in inland waters of Lithuania in 2005–2008, *Acta Zoologica Lituanica*, 19, 99-108.
19. Rolbiecki L, 2004, Distribution of *Posthodiplostomum cuticola* (Nordmann, 1832) (Digenea: Diplostomatidae) metacercariae in Cyprinids of the Vistula lagoon, Poland, *Arch Pol Fish*, 12, 93-8.
20. Rolbiecki L, 2006, Correlation between the occurrence of parasites and body length of roach, carp bream, European perch, zander, and ruffe in the Vistula Lagoon estuary, *Int J Oceanogr Hydrobiol*, 36, 257-67.
21. Schaperclaus WM, 1990, *Fischkrankheiten*, Akademie Verlag, Berlin. 5. Auflage.
22. Schuster R, Wanjek K, Schein E, 2001, Investigations on the occurrence of muscle metacercariae in the roach (*Rutilus rutilus*) from Berlin waters. A contribution to the food hygienic importance of indigenous freshwater fish, *Arch Lebensmittelhyg*, 52, 102-4.
23. Shukerova S, 2005, Helminth fauna of the Prussian carp, *Carassius gibelio* (Bloch, 1782), from the Srebarna biosphere reserve, *Trakia J Sci*, 3, 36-40.
24. Sonin MD, 1986, Key to the Trematode Parasites of Fish-Eating Birds in Palearctic Region, Nauka, Moscow.
25. Soylu E, 2006, Some metazoan parasites (Cestoda, Trematoda and Mollusca) of *Blicca bjoerkna* Linnaeus, 1758 from Sapanaca lake, Turkey, *J Fish Aquat Sci*, 20, 33-42.
26. Teixeira-de Mello F and Eguren G, 2008, Prevalence and intensity of black-spot disease in fish community from a subtropical stream (Santa Lucía river basin, Uruguay), *Limnetica*, 27, 251-8.
27. Zrnčić S, Oraić D, Mihaljević Z, Čaleta M, Zanella D, Jelić D et al., 2009, First observation of *Posthodiplostomum cuticola* (Nordmann, 1832) metacercariae in cypriniformes from Croatia, *Helminthologia*, 46, 112-6.

POSTODIPILOSTOMATOZA NA RIBNJAKU U SRBIJI

MARKOVIĆ MAJA, ĆIRKOVIĆ M, ALEKSIĆ NEVENKA, MILOŠEVIĆ NIKOLINA,
BJELIĆ-ČABRILLO OLIVERA, LJUBOJEVIĆ DRAGANA, AKSENTIJEVIĆ KSENIJA
i RADOJIĆIĆ MARINA

SADRŽAJ

Postodiplostomatoza je oboljenje mlađih kategorija slatkovodnih riba izazvano infekcijom metecerkarijama trematode *Posthodiplostomum cuticola*. Promene se zapažaju u vidu crnih cista lokalizovanih prvenstveno u koži, subepidermalnom tkivu i na perajima. Najčešće se javlja kod vrsta riba familija *Cyprinidae* i *Cobitidae*. Iako je infekcija duži niz godina prisutna u otvorenim vodama, u radu je opisan prvi nalaz infekcije kod riba iz ribnjaka u Srbiji. Postodiplostomatoza je dijagnostikovana kod belog amura (*Ctenopharyngodon idella*) i sivog tolstolobika (*Aristichthys nobilis*). Promene su bile karakteristične, makroskopski vidljive kao tamnosiva do crna kružna polja diskoloracije najčešće na perajima. Njihova prosečna veličina iznosila je $946.5 \pm 25.19 \mu\text{m}$ kod belog amura i $944.5 \pm 23.50 \mu\text{m}$ kod tolstolobika.