

Case report

A RARE CASE OF CANINE METASTATIC SPERMATOCYTIC TUMOR WITHOUT SARCOMATOUS AND ANAPLASTIC VARIANTS

Eun-Joo LEE¹, Jae-Hyuk YIM¹, Myung-Jin CHUNG¹, Jin-Kyu PARK¹, Il-Hwa HONG², Kyu-Shik JEONG^{1*}

¹College of Veterinary Medicine, Department of Veterinary pathology Kyungpook National University, Daegu City, Republic of Korea; ²College of Veterinary Medicine, Department of Veterinary pathology Gyeongsang National University, Chinju City, Republic of Korea

(Received 18 April, Accepted 04 June 2021)

Spermatocytic tumor is a rare testicular tumor, which is originated from gonocytes. It is characterized by the histological feature of tripartite which is composed of large, medium, and lymphocyte-like small cells. It is well-known that spermatocytic tumor is benign, thus a good prognosis is expected after simple resection. Metastatic spermatocytic tumor is extremely rare and usually accompanied by histological variants including sarcomatous changes and anaplastic variants. In this case, however, we report a canine metastatic spermatocytic tumor without prominent sarcomatous changes and anaplastic variants. The mass was composed of three kinds of cells including large, medium, and small cells with high pleomorphism. The neoplastic cells had an indistinct cytoplasmic border and mitotic figures were frequently observed. The primary spermatocytic tumor metastasized to the abdominal organs one month after the resection, and the dog died 13 months after the surgery. Thus, careful follow-up is recommended after surgical resection of canine spermatocytic tumor even though metastasis in spermatocytic tumors is rare.

Key words: Canine testicular tumor, Canine spermatocytic tumor, Metastasis, Malignancy

INTRODUCTION

The testicular tumor is the second most frequently reported tumor in male dogs, which accounts for 7 ~ 16 % of tumors in intact male dogs [1]. The most common testicular tumors in dogs are seminoma, Sertoli cell tumor, and Leydig cell tumor with similar incidence. Seminoma is classified into two subtypes; one is classical seminoma and the other is spermatocytic tumor depending on the histopathological and immunohistochemical characteristics, malignancy, and incidence [2]. The classical

*Corresponding author: e-mail: jeongks@knu.ac.kr

seminoma represents malignancy with high incidence rate, whereas spermatocytic tumor is benign and non-aggressive, which hardly metastasizes to other organs. Although rare, there are few cases of metastatic spermatocytic tumors in humans that metastasize to the liver, lung, lymph nodes, and brain [3-6]. Most of metastatic spermatocytic tumors accompany histological variants including sarcomatous transformation and anaplastic variants. It is previously reported that the origin of the metastasized tumor is a sarcomatous component in human spermatocytic tumors [3]. Thus, it has been suggested that sarcomatous transformation is one of the predictors of metastasis in spermatocytic tumors [7]. Here, however, we report a canine metastatic spermatocytic tumor, which is an extremely rare case even without any sarcomatous and anaplastic changes.

CASE PRESENTATION

An eight-year-old male Maltese was admitted to the animal hospital with abdominal distention. He had cryptorchidism. There were no significant clinical symptoms including anorexia and inactivity. On X-ray examination, a globule-shaped opaque mass was observed in the left abdomen (Figure 1A). The size of the mass rapidly increased upon the X-ray examination and the mass was surgically removed. The mass was well-circumscribed from the adjacent tissue and encapsulated with fibrous tissue. The mass was slightly firm with a gelatinous texture. The mass was globule-shaped and grayish-white and reddish in color. The size of the mass was 8×8×10 cm³, which was remarkably large when considering that the body weight of the dog was 3.32 kg (Figure 1B). The cut surface revealed a solid form with hemorrhage and mild edema. One month after the tumor resection, he presented symptoms of vomiting, diarrhea, and cough. Metastases to the abdominal organs including liver, spleen, and urinary bladder were observed on sonography and ascites was remarkable. He died 13 months after the tumor resection. For histopathological analysis, the mass was fixed in 10% neutral formalin. The fixed tissue was routinely processed, embedded in paraffin, and cut into 6 μm thickness. Hematoxylin-eosin (H&E) staining was performed. For immunohistochemistry, the antigens were retrieved using heated-sodium citrate buffer. After antigen retrieval, blocking, primary antibody reaction, and secondary antibody reaction were sequentially performed at room temperature for 1 hour each using Vectastatin Elite ABC kit. The primary antibodies used in this study were as follows: anti-vimentin, anti-CD30, anti-OCT3/4, and anti-CK8/18 antibody (Santa cruz).

On microscopic findings, the mass had a tripartite cell population which is composed of large, medium, and small lymphocyte-like cells, which is one of the main features of spermatocytic tumor that distinguishes it from other testicular tumors. The neoplastic cells had large and oval shaped nuclei and scant cytoplasm. The nuclei of the neoplastic cells were vesicular and overlapped, representing moderate anisokaryosis. Also, the neoplastic cells had densely packed crowded nuclei. Mitotic figures were

frequently observed. Importantly, it was hard to find sarcomatous changes that are usually accompanied by metastatic spermatocytic tumor.

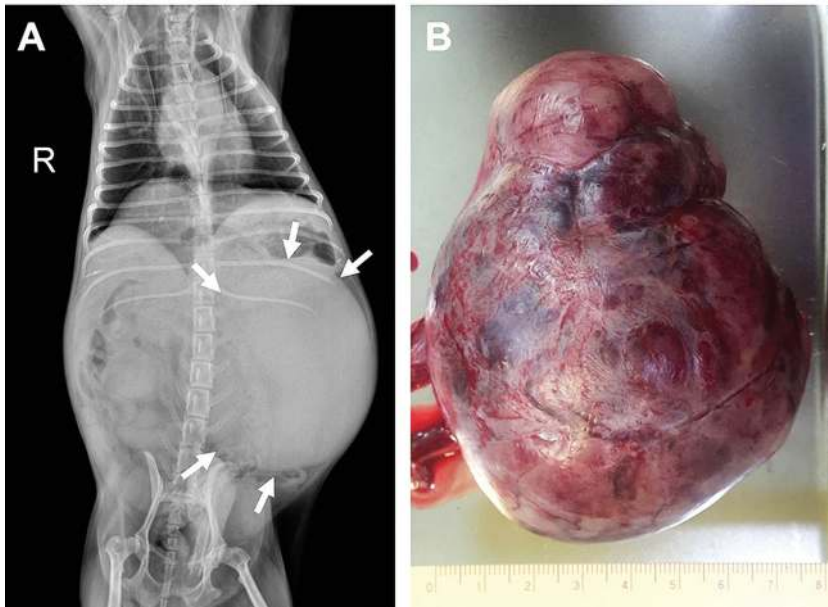


Figure 1. (A) X-ray imaging. A globule-shaped opaque region in the abdominal cavity. Arrows indicate the margin of the mass. (B) Gross observation. The mass was encapsulated with collagen fiber and well-circumscribed from the adjacent tissue.

It is important to make a differential diagnosis in testicular tumors, since testicular tumors share similar histological features, especially when representing high pleomorphism and malignancy. Mainly, the spermatocytic tumor needs to be differentiated from classical seminoma, embryonal carcinoma, and testicular lymphoma. The classical seminoma presents a fibrovascular septum with remarkable infiltration of lymphocytes and the neoplastic cells of classical seminoma have a distinct cytoplasmic border. However, this case did not have a fibrovascular septum and remarkable lymphocyte infiltration, as well as the neoplastic cells had indistinct cytoplasmic borders, which leads to making a diagnosis as spermatocytic tumor, not classical seminoma. Unlike testicular lymphoma which has pale and abundant cytoplasm with a well-defined cytoplasmic membrane, this case represents amphophilic cytoplasm with indistinct cytoplasmic borders, except for a few clear cell-like cells. Due to the indistinct cytoplasmic membrane and aggressive features including metastasis and crowded nuclei, embryonal carcinoma was regarded as one of the possible diagnoses. However, the possibility of embryonal carcinoma could be excluded since this case did not represent epithelial differentiation which is one of the critical histological characteristics of embryonal carcinoma (Figure 2).

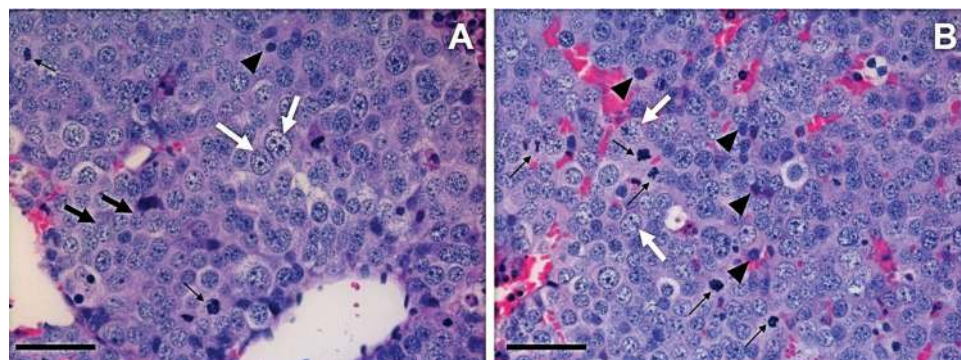


Figure 2. Microscopic observation. **(A)** and **(B)** The mass was solid and sheet form. Tripartite cellular population was observed including large (white arrows), intermediate (black arrows), and small (arrow head) size cells. Mitotic figures were frequently observed (thin arrows). The neoplastic cells had large and oval nuclei and scant cytoplasm. Mitotic figures were frequently observed. Scale bar = 50 μ m.

Table 1. Immunohistochemistry of testicular tumors

	The presented case	Spermatocytic tumor	Classical seminoma	Embryonal cell carcinoma
CD30	-	-	-	+
Oct3/4	-	-	+	+
Vimentin	-	-	-	-
CK8/18	-	-	-	+

The immunohistochemistry is also helpful for the differential diagnosis of spermatocytic tumor from other testicular tumors, especially when the tumor does not represent typical histological features due to poor differentiation and high pleomorphism. It is known that spermatocytic tumors are negative for the staining of OCT3/4, CD30, placental alkaline phosphatase (PLAP), vimentin, and AE1/AE3, whereas classical seminoma and embryonal carcinoma are positive for PLAP and OCT3/4 [8]. This case was negative for CD30, OCT3/4, and vimentin (Figure 4). CD30 is a valuable marker to distinguish seminoma from embryonal carcinoma since seminoma is negative for CD30 whereas embryonal carcinoma is positive for CD30 [9]. The positivity for OCT3/4 is well-known as a critical marker of classical seminoma and embryonal cell carcinoma, whereas spermatocytic tumor is negative for OCT3/4 [10]. Thus, the negativity for OCT3/4 in the present case may exclude the possibility of classical seminoma and embryonal carcinoma though there is a report that canine classical seminoma presents little immunoreactivity to OCT3/4 unlike human classical seminoma [9]. Vimentin is a well-known mesenchymal cell marker and the negativity for vimentin helps to exclude Sertoli cell tumor in the differential diagnosis. Thus, this case was diagnosed as a spermatocytic tumor based on the histopathological and immunohistochemical characteristics (Figure 3).

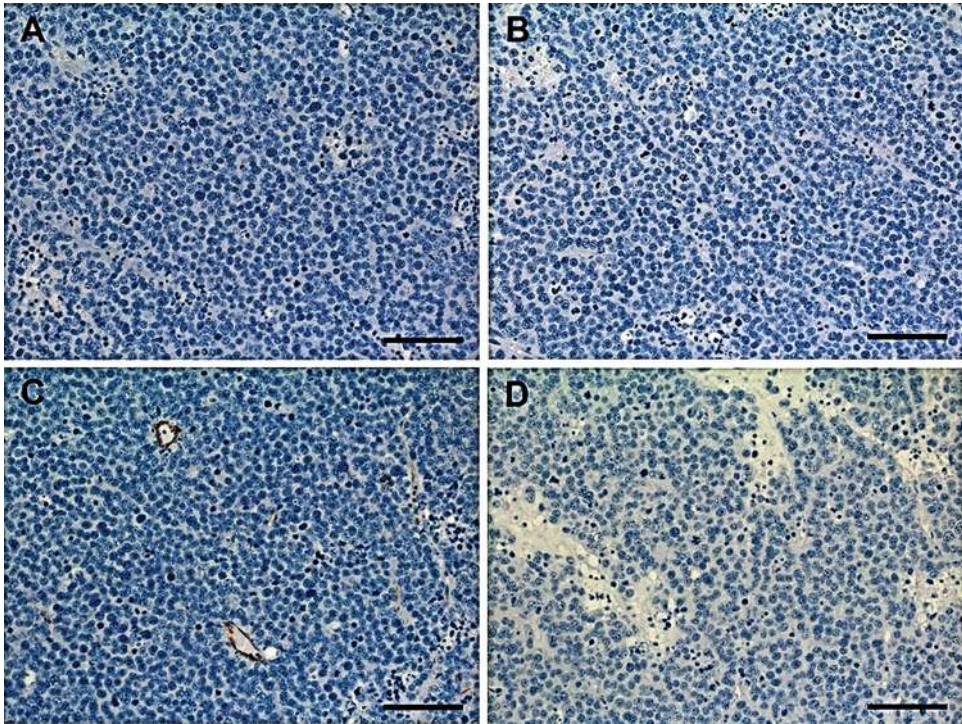


Figure 3. Immunohistochemical findings. The mass was negative for (A) CD30, (B) OCT3/4, (C) vimentin, (D) CK8/18. Scale bar = 200 μ m.

The canine seminoma used to be classified into three subtypes; intratubular type without invasion, intratubular type with invasion, and diffuse type [11]. Recently, however, a growing body of cases has been reported that the canine seminoma can be classified into two subtypes like human and each canine subtype resembles human counterparts. Grieco *et al.* revealed that canine seminomas are classified into classical seminoma and spermatocytic tumor based on their distinct histochemical and immunohistochemical features. The canine classical seminoma is positive for placental alkaline phosphatase (PLAP) and periodic acid-Schiff (PAS) staining, whereas the canine spermatocytic tumor is negative for both stainings. [12]. Also, canine seminoma is divided into two groups in terms of angiogenesis evaluated by microvessel density and vascular parameters. It was reported that canine classical seminoma presented significantly higher microvessel density and increased vascular parameters than spermatocytic tumor [13].

It has been suggested that the size of human spermatocytic tumor is correlated to the incidence of metastasis. It is reported that the average size of metastatic spermatocytic tumor was 92.5 mm, while 67.5 mm in non-metastatic spermatocytic tumor, indicating that the metastatic spermatocytic tumor is statistically significantly larger than the non-metastatic one [7]. Considering that it was a small dog weighing 3.32 kg, the size

of the tumor was remarkably large ($8 \times 8 \times 10 \text{ cm}^3$) in this case. The metastasis in this case may have a correlation to the size of the mass. The larger tumors have more chances to be physically adjacent to large blood vessels, which increase the possibility of neoplastic cells to enter the blood stream. Also, the hypoxia condition caused by the rapid proliferation of neoplastic cells of large tumors stimulates neovascularization [14]. Neovascularization is required to supply nutrients and oxygen to actively dividing neoplastic cells and remove waste. The immature blood vessels formed by neovascularization show high permeability, thus enhance tumor cells to enter the bloodstream [15]. Therefore, the large tumor, especially presenting rapid growth, may be one of the predictors for metastasis even though spermatocytic tumor is typically non-metastatic.

Cryptorchidism is one of the risk factors of testicular tumors, especially Sertoli cell tumors and seminomas in both humans and dogs [16, 17]. It is reported that testes with cryptorchidism have a 13.6 times higher incidence of testicular tumor than normal scrotal testes which were evaluated in 410 cases [17]. It has been reported in patients who underwent orchiopexy that the longer the exposure time to cryptorchidism is, the higher the incidence of testicular tumor is [18]. Also, the testicular tumor tends to show higher malignancy when accompanying cryptorchidism [19]. From the authors' knowledge, however, there is a paucity of studies on the correlation between cryptorchidism and metastasis of spermatocytic tumor, which may be due to the extremely low incidence of metastatic spermatocytic tumor in dogs. In spermatocytic tumors, cryptorchidism may affect incidence, malignancy, and metastasis of spermatocytic tumors as in other testicular tumors, by providing an optimal tumor microenvironment such as higher temperature than scrotal testes.

In this study, we reported canine metastatic spermatocytic tumor, which is an extremely rare case. It suggests that the possibility of metastasis of spermatocytic tumor without sarcomatous and anaplastic changes. When considering the low incidence of spermatocytic tumors, the metastasis without histological variants in spermatocytic tumors provides valuable information for further treatment strategy. It is recommended to continue follow-up after orchiectomy or surgical removal of spermatocytic tumor, considering the possibility of metastasis as shown in this case, although very rare.

Acknowledgement

This work was supported by the National Research Foundation of Korea (NRF) grant funded by the Korea Government (grant number:NRF-2017R1E1A1A01072781).

Author's contribution

EJ carried out the wholes diagnostic processing and alignment and drafted the manuscript. JH, MJ, JK and IH carried out the specific immunohistochemistry. EJ and KS conceived of the study, and participated in its design and coordination and helped to draft the primary manuscript and further finalized draft. All authors read and approved the final manuscript.

Declaration of conflicting interests

The author(s) declared no potential conflicts of interest with respect to the research, authorship, and/or publication of this article.

Statement of Informed Consent

The owner understood procedure and agrees that results related to investigation or treatment of their companion animals, could be published in Scientific Journal Acta Veterinaria-Beograd.

REFERENCES

1. Hohsteter M, Artukovic B, Severin K, Gudan Kurilj A, Beck A, Sostaric-Zuckermann IC, Grabarevic Z: Canine testicular tumors: two types of seminomas can be differentiated by immunohistochemistry. *BMC Vet Res* 2014, 10:169.
2. Ulbright TM: Recently described and clinically important entities in testis tumors: a selective review of changes incorporated into the 2016 classification of the World Health Organization. *Arch Pathol Lab Med* 2019, 143(6):711-721.
3. Jozef Matoska DO, Horank M: Metastatic spermatocytic seminoma. a case report with light microscopic, ultrastructural, and immunohistochemical findings. *Cancer* 1988, 62:1197-1201.
4. Steiner H, Gozzi C, Verdorfer I, Mikuz G, Bartsch G, Hobisch A: Metastatic spermatocytic seminoma - an extremely rare disease. *Eur Urol* 2006, 49(1):183-186.
5. Choi SK, Kim T, KH Yoo: Spermatocytic seminoma with brain metastasis. *Pathol Oncol Res* 2017, 23(1):223-224.
6. Josef Matoska AT: Spermatocytic seminoma associated with rhabdomyosarcoma. *Am J Clin Pathol* 1989, 94(1):89-95.
7. Grogg JB, Schneider K, Bode PK, Wettstein MS, Kranzbuhler B, Eberli D, Sulser T, Beyer J, Hermanns T, Fankhauser CD: A systematic review of treatment outcomes in localised and metastatic spermatocytic tumors of the testis. *J Cancer Res Clin Oncol* 2019, 145(12):3037-3045.
8. Ulbright TM: The most common, clinically significant misdiagnoses in testicular tumor pathology, and how to avoid them. *Adv Anat Pathol* 2008, 15(1):18-27.
9. Yu CH, Hwang DN, Yhee JY, Kim JH, Im KS, Nho WG, Lyoo YS, Sur JH: Comparative immunohistochemical characterization of canine seminomas and Sertoli cell tumors. *J Vet Sci* 2009, 10(1):1-7.
10. Jones TD, Ulbright TM, Eble JN, Baldrige LA, Cheng L: OCT4 staining in testicular tumors: a sensitive and specific marker for seminoma and embryonal carcinoma. *Amer J Surg Pathol* 2004, 28(7):935-940.
11. Kennedy PC: Histological classification of tumors of the genital system of domestic animals. *Armed Forces Inst. of Pathology* 1998.
12. Grieco ERV, Rondena M, Ciampi V, Finazzi M: Classical and spermatocytic seminoma in the dog: histochemical and immunohistochemical findings. *J Comp. Path* 2007, 137:41-46.

13. Kim JH, Yu CH, Yhee JY, Im KS, Kim NH, Sur JH: Canine classical seminoma: a specific malignant type with human classifications is highly correlated with tumor angiogenesis. *BMC Cancer* 2010, 10:243.
14. Diez-Torre A, Silvan U, Diaz-Nunez M, Arechaga J: The role of microenvironment in testicular germ cell tumors. *Cancer Biol Ther* 2010, 10(6):529-536.
15. Zetter BR: Angiogenesis and tumor metastasis, *Ann Rev Med* 1988, 49:407-424.
16. Albert PYC, Taiching L, Yeh JS, Lin CT, Liu CH: A 12-year retrospective study of canine testicular tumors, *J Vet Med Sci* 2009, 71(7):919-923.
17. Hayes HM, Pendergrass TW: Canine testicular tumors: epidemiologic features of 410 dogs. *Int J Cancer* 1976, 18:482-487.
18. Andreas LR, Pettersson A, Nordenskjold A, Kaijser M, Akre O: Age at surgery for undescended testis and risk of testicular cancer, *New Eng J Med* 2007, 356(18):1835-1841.
19. Benson RC, Beard CM, Kelalis PP, Kurland LT: Malignant potential of the cryptorchid testis. *Mayo Clinic Proceedings, Elsevier*, 1991, pp. 372-378.

REDAK SLUČAJ METASTATSKOG SPERMATOCITNOG TUMORA KOD PSA BEZ SARKOMATOZNIH I ANAPLASTIČNIH PROMENA

Eun-Joo LEE, Jae-Hyuk YIM, Myung-Jin CHUNG, Jin-Kyu PARK, Il-Hwa HONG, Kyu-Shik JEONG

Spermatocitni tumor je redak tumor testisa, koji potiče od gonocita. Karakteriše ga histološki nalaz tri morfološka tipa ćelija, a sastoji se od velikih, srednjih i limfocitima sličnih malih ćelija. Dobro je poznato da je spermatocitni tumor benignog ponašanja pa se očekuje dobra prognoza nakon jednostavne resekcije. Metastatski spermatocitni tumor izuzetno je redak i obično je praćen histološkim varijacijama, uključujući sarkomatozne i anaplastične promene. U ovom slučaju, međutim, opisan je metastatski spermatocitni tumor bez izraženih sarkomatoznih promena i anaplastičnih varijanti. Masa se sastojala od tri vrste ćelija, uključujući velike, srednje i male ćelije sa visokim pleomorfizmom. Neoplastične ćelije su imale nejasnu citoplazmatsku granicu i često su primećene mitotičke figure. Primarni spermatocitni tumor metastazirao je na trbušne organe mesec dana nakon resekcije, a pas je uginuo 13 meseci nakon operacije. Stoga se preporučuje pažljivo praćenje nakon hirurške resekcije spermatocitnog tumora mada su metastaze u spermatocitnim tumorima retke.