







QUANTITATIVE PANCREATIC ULTRASONOGRAPHY AND Vcheck cPL RAPID TEST IN DOGS WITH SUSPECTED ACUTE PANCREATITIS

Somkiat HUAJANTUG¹, Paranee YATMARK^{2*}, Vitchayarat ITTHICHAIVASAN³, Sarunya NUAENGSRI³, Satinee SRITHIP³, Pruksa JULAPANTHONG⁴

¹Department of Clinical Sciences and Public Health, The Faculty of Veterinary Science, Mahidol University, Thailand; ²Department of Pre-Clinical and Apply Animal Science, The Faculty of Veterinary Science, Mahidol University, Thailand; ³The Faculty of Veterinary Science, Mahidol University, Thailand; ⁴Prasuarthorn Animal Hospital, Thailand.

(Received 10 January, Accepted 26 April 2024)

The aim of this study was to evaluate the importance of quantitative ultrasonography in the diagnosis of acute pancreatitis in dogs, as well as to examine the correlation between the results of ultrasound examination and the Vcheck cPL rapid test in dogs with suspected acute pancreatitis. A total of 37 dogs were included to the study – 15 healthy dogs and 22 dogs with gastrointestinal clinical signs which had at least 1 out of 3 criteria (vomiting, cranial abdominal pain and jaundice). Serum was collected to evaluate cPL level by Vcheck cPL rapid test. A score 0 implied the Vcheck cPL Rapid test result was less than 200 ng/ml. A score 1 implied Vcheck cPL Rapid test result between 200 and 400 ng/ml, and a score 2 more than 400 ng/ml. Ultrasound was performed in all dogs in order to investigate the pancreatic lesions within 48 hours and evaluate the level of pancreatitis by score from 0 to 2. The criteria for pancreatitis on ultrasonograms included enlargement or irregularity of the pancreas, hypochoic areas of the pancreas and hyperechoic mesentery surrounding the pancreas. An ultrasound assessment of pancreatitis implied: score 0 when none of the criteria was present. Score 1 when 1-2 from 3 criteria were present, and score 2 when all of the 3 criteria were present. Correlation between Vcheck cPL Rapid test and pancreatic ultrasonography was examined. The results indicate that agreement of Vcheck cPL Rapid test and pancreatic ultrasonography had kappa values of 0.71 which are in the “moderate” agreement range. This means that both Vcheck cPL Rapid test and ultrasonography should be used in the diagnostics of acute pancreatitis in daily clinical practice. Additionally, quantitative ultrasound assessment can be helpful in distinguishing acute pancreatitis from normal pancreas.

Keywords: acute pancreatitis, dog, quantitative ultrasonography, Vcheck cPL

*Corresponding author: e-mail: paranee.yat@mahidol.edu

INTRODUCTION

Pancreatitis is the most common disease of the exocrine pancreas that has an aggressive progression and sometimes is a life-threatening disorder in dogs [1]. Acute pancreatitis implies a rapid inflammation of the dog's pancreas within 2 weeks, often with a neutrophilic infiltrate. Because there is no fibrosis or chronic inflammation that disrupts the normal architecture of the pancreas, as in the case of chronic pancreatitis, acute pancreatitis is a completely reversible process [2]. Clinical signs of acute pancreatitis are often non-specific, and include depression, anorexia, weakness, dehydration, arrhythmia, dyspnea, vomiting, cranial abdominal pain, diarrhea, jaundice and finally leads to death [3].

Currently, abdominal ultrasonography and the measurement of serum pancreatic lipase activity are considered to be the most useful diagnostic modalities for pancreatitis [4]. The gold standard in the diagnostics of canine acute pancreatitis diagnosis is biopsy performed during laparotomy in order to obtain a histopathological diagnosis, however this is not the practical way because it is invasive and causing more damage to the pancreas [5]. Canine pancreatic lipase immunoreactivity can be estimated by Snap and Spec cPL test. Snap cPL test provides the result in just 10 minutes. The result can be positive or negative but the level of cPL cannot be determined. In contrast to this, Spec cPL is more useful in terms of disease progression assessment because Spec cPL provides the exact level of cPL, but it takes 12-24 hours to get the result [6].

Recently, the Vcheck cPL Rapid test, is available commercially. This test uses Europium fluorescent which is claimed to be more accurate than the general fluorescent particle with the stimulating wavelength and emitting wavelength that is more specific and Vcheck can show the result in the exact level number in just 5 minutes [7]. However, the overall accurate clinical diagnostic efficacy of acute pancreatitis remains challenging and controversial. New diagnostic methods are needed.

Ultrasonography has the advantage of being a non-invasive, safe diagnostic method and relatively low in cost. Information can be obtained immediately and the complete abdomen can be evaluated at the same time. Abdominal ultrasonography can provide specific information such as size, shape and homogeneity of the pancreas. Moreover, it can help in the differentiation of various pathological conditions of the pancreas such as abscesses, pseudocysts, nodular hyperplasia and neoplasia. Acute pancreatitis results in an enlarged, irregular, hypoechoic pancreas, hyperechoic surrounding mesenteric fat secondary to inflammation and saponification, focal peritoneal effusion, and dilation of the gallbladder and common bile duct [8]. Ultrasound has been reported to be comparable to CT in assessment of acute pancreatitis in people [9]. The use of histogram-base parameters calculated by means of computer-assisted image analysis software to objectively assess the echogenicity and the texture of parenchymal organs has become a common tool in human medicine [10].

Because canine pancreatic lipase measurement could be false positive this cannot confirm the disease while ultrasonography is dependent on the disease severity, the skill and experience of the ultrasonographer and the equipment quality [1]. However, either the measurement of pancreatic lipase or pancreatic ultrasonography are most often used in clinical practice. Prompt and accurate diagnosis facilitates early therapy, which improves the chances of survival.

The aim of this study was to quantify the ultrasound changes as possible signs of inflammation, as well as to evaluate their agreement with results of Vcheck cPL Rapid test in dogs with suspected acute pancreatitis. Quantitative ultrasound changes as possible signs of inflammation occur in canine pancreatitis; therefore, quantitative ultrasound could potentially be useful as a new diagnostic tool in the diagnostics of pancreatitis in dogs.

MATERIALS AND METHODS

Study overview and case selection

Thirty-seven dogs from the Prasuarthorn animal hospital were included in this study. There were divided in two groups: 15 healthy dogs and 22 client-owned dogs with gastrointestinal clinical signs associated with pancreatitis. Signs of gastrointestinal disease included at least 1 of the following: vomiting, cranial abdominal pain and jaundice. Blood samples were collected from each patient at the time the Vcheck cPL Rapid Tests were performed. In addition, pancreatic ultrasonography was performed within 48 hours. This study was approved by the Animal Care and Use Committee of the Faculty of Veterinary Science, Mahidol University (MUVS-2018-06-25). All owners of the patients enrolled in the study signed an informed consent agreement.

Vcheck cPL Rapid test

Serum was submitted to a commercial laboratory, where a Vcheck cPL Rapid test immunoassay was performed and the results are shown in Table 1. A Vcheck cPL Rapid test score 0 was assigned when the Vcheck cPL Rapid test result of <200 ng/ml is considered to be not consistent with pancreatitis, whereas score 2 was assigned when a result of 400 ng/ml is consistent with pancreatitis. Score 1 was assigned when the Vcheck cPL Rapid test result of 200-400 ng/ml is considered to be equivocal for the diagnosis of pancreatitis.

Ultrasonographic pancreatic assessment score

All abdominal ultrasound examinations were performed and retrospectively evaluated by three veterinary radiologists blinded to case history and results of diagnostic testing including Vcheck cPL assay. Scoring criteria for ultrasound findings included

enlargement or irregularity of the pancreas, the presence of hypoechoic areas of the pancreas and hyperechoic mesentery surrounding the pancreas are shown in Table 1.

Table 1: Scoring criteria for Vcheck cPL Rapid test and ultrasound findings.

Score	Vcheck cPL Rapid test (ng/ml)	Ultrasound findings
0	< 200	none of the criteria
1	200 – 400	1-2 out of 3 criteria
2	> 400	all of the 3 criteria

Ultrasound examinations

Ultrasound investigations were performed using the ultrasound device LOGIQ P6: GE Healthcare, Thailand. The animals were under general anesthesia during the entire procedure. Diazepam in a dose of 0.1-0.5 mg/kg and tramadol in a dose of 2-4 mg/kg were used as premedication, which were administered intravenously into the anterior cephalic vein. Propofol was used as an anesthetic, which was also administered intravenously in a dose of 5 mg/kg. Acetate Ringer's solution was applied in the same way (iv) at a rate of 10 ml/kg/h, as well as cephalexin in a dose of 15-30 mg/kg. The depth of anesthesia, pulse rate, respiratory rate, and the response of the nervous system (palpebral reflex, muscular reflex, deep pain) were monitored during the procedure.

Throughout ultrasonography dogs were placed in dorsal position. All features of the pancreatic images were described for size, echogenicity, structure and shape. Ultrasound examination in the form of a 15 seconds long movie was recorded on the hard disk drive enclosed in the ultrasound system. The frequency of ultrasound elastography was set at 10-12 MHz.

Quantitative images analysis

Semi-quantitative analysis of the histogram of the pancreas area was also performed by analyzing images obtained by ultrasonography. The digital images were analyzed with ImageJ Ver.1.47i software (developed at the National Institute of Health, Maryland, USA). First, a true color image was transformed to an 8-bit grayscale image in which the grayscale intensity ranged from 0 to 256. The region of interest (ROI) included the entire pancreas area, which was visible in gray scale imaging. The same ROI was copied onto an observed area in ultrasound image. The gray values of individual pixels were analyzed, and a histogram was constructed. The minimal gray value detected in tissues was considered as the threshold for detection of areas representing inflammation tissue. Then, the gray values of the pixel above the threshold were integrated.

Statistical Analysis

Statistical analysis was performed with IBM SPSS software version 21.0 (Armonk, NY). Agreement between Vcheck cPL Rapid test and pancreatic ultrasonography was performed by using weighted kappa coefficient (κ) from commercial software. Values between 0 and 0.20 indicated slight agreement, values between 0.21 and 0.40 indicated fair agreement, values between 0.41–0.60 indicated moderate agreement, values between 0.61 and 0.80 indicated substantial agreement, and values between 0.81 and 1 indicated almost perfect agreement. The mean and standard deviation (SD) were calculated as well as histogram analyses of ROI. The mean score and histogram analysis was compared between the healthy animals and dogs with pancreatitis using the Mann–Whitney U-test. Statistical significance was set at a p-value <0.05.

RESULTS

Animals

The study population consisted of 22 dogs with pancreatitis including 11 male and 11 female dogs. Ages ranged from 2 to 17 years (median, 10 years). Weights ranged from 3 to 33 kg (median, 7.3 kg). Breeds included mixed breed dogs (n = 8), Poodle (n = 5), Chihuahua (n = 2), Pomeranian (n = 2), Shizhu (n = 3) and Beagle (n = 2). Spec cPL was <200 ng/L in 6/22 (27.27%) dogs, between 200 and 400 ng/L in 0/22 (0%) dogs, and >400 in 16/22 (72.73%) dogs. Signalment and selected variables of dogs in the pancreatitis and control group are shown in Table 2.

Table 2: Signalment and selected variables of dogs with pancreatitis and the control group.

Signalment	Pancreatitis group (n=22)	Control group (n=15)
Age (year old) ^a	10 (2 – 17)	9 (2 – 16)
Body weight (kg) ^a	7.3 (3 – 33)	5 (3 – 30)
Sex	11 M, 11 F	6 M, 9 F
Breed	Mixed breed dogs (8), Poodle (5), Chihuahua (2), Pomeranian (2), Shizhu (3) and Beagle (2)	Mixed breed dogs (7), Poodle (2), Chihuahua (3), Pomeranian (1), and Shizhu (2)

M, Male; F, Female;

^aValues expressed as median (range)

Vcheck cPL Rapid test results

Pancreatic ultrasonography within 48 hours of Vcheck cPL rapid test was performed in 22/22 (100%) dogs with suspected acute pancreatitis and Vcheck cPL rapid test 6/22 (27.27%) dogs were in score 0 (<200 ng/ml), no dog was in score 1 (200-400 ng/ml) and 16/22 (72.72%) dogs were in score 2 (>400 ng/ml).

Pancreatic ultrasound finding

Ultrasonographic examination results showed that 5/22 (22.7%) dogs had score 0, 4/22 (18.2%) dogs had score 1 and 13/22 (59.1%) dogs had score 2. The results showed that 12/22 (54.54%) dogs were diagnosed by both methods and had the same diagnosis score results and 10/22 (45.45%) dogs had different diagnosis score results. Normal pancreas in conventional ultrasound of healthy dogs are shown in Figure 1.

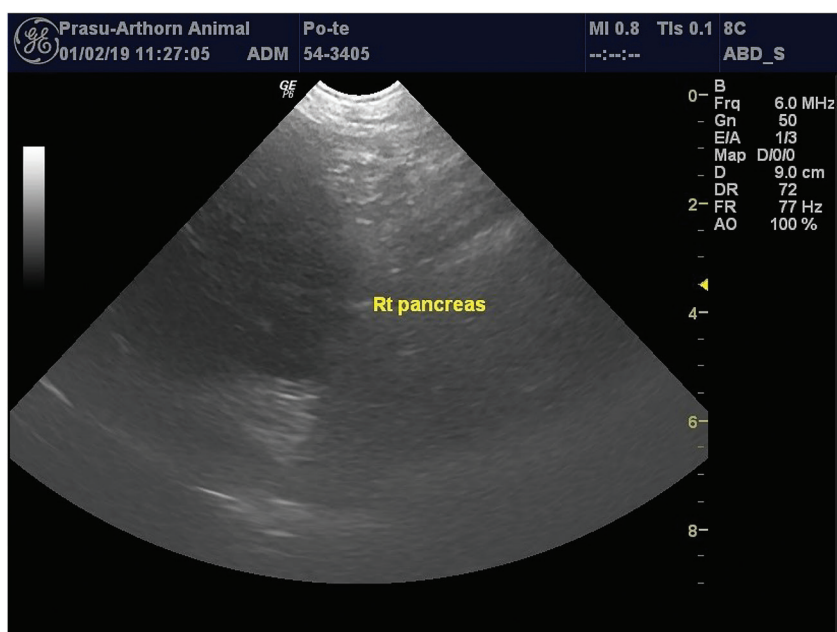


Figure 1. Ultrasound image of pancreatitis score “0”. Pancreatic parenchyma has similar echogenicity to the surrounding mesenteric fat. Normal thickness and regular contour of pancreas.

Vcheck cPL Rapid test and Ultrasonography score

The Vcheck cPL Rapid test and Ultrasonography score in dogs with suspected acute pancreatitis are shown in Table 3. An abdominal ultrasound examination: score “0” was assigned when found none of criteria is considered to be not consistent with pancreatitis (Figure 1). Score “1” was assigned when found 1-2 from 3 criteria is considered to be equivocal for the diagnosis of pancreatitis (Figure 2).

Table 3: Vcheck cPL Rapid test score and ultrasonography score in dogs with suspected acute pancreatitis.

		Ultrasonography score			
		0	1	2	Total
Vcheck	0	3	2	1	6
Rapid test	1	0	0	0	0
Score	2	5	1	10	16
Total		8	3	11	22

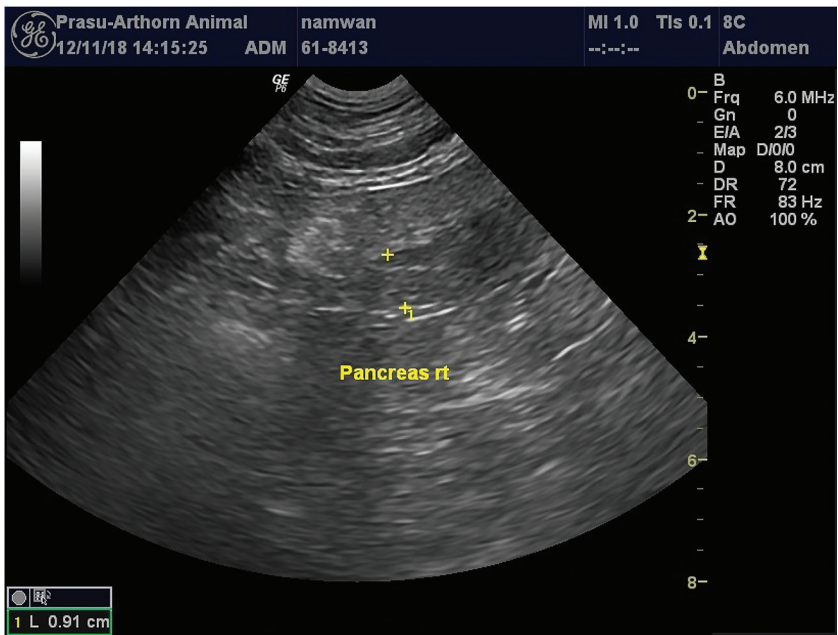


Figure 2. Ultrasound image of pancreatitis score “1”. The homogeneous hypoechoic parenchyma and normal thickness of pancreas with mild hyperechoic surrounding mesenteric fat.

Score “2” was assigned when found all of 3 criteria is consistent with pancreatitis (Figure 3).

In weighted kappa coefficient (k) analysis resulting in 0.71 is in the “moderate” agreement range between Vcheck cPL rapid test and ultrasonography results.

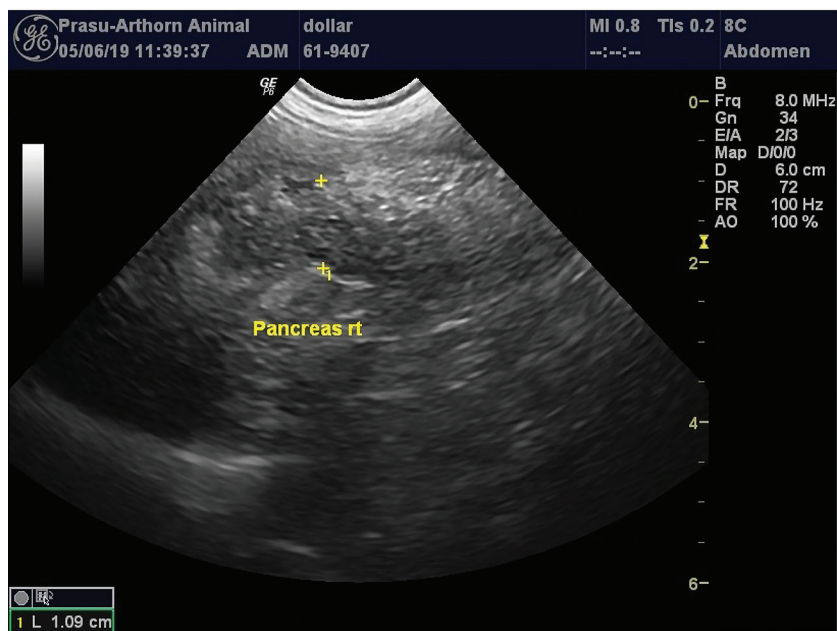


Figure 3. Ultrasound image of pancreatitis score “2”. The diffuse hypoechoic parenchyma, thickness and irregular contour of pancreas with hyperechoic surrounding mesenteric fat.

Quantitative ultrasonographic images analysis

The mean histograms of the left pancreas (2895 ± 524) and right pancreas (2491 ± 308) in healthy dogs were significantly higher for left pancreas (1577 ± 423), and right pancreas (1627 ± 460) in the pancreatitis group, respectively. The group of dogs with pancreatitis also showed a decrease in the mean histogram of every score grading (Figure 4). This result demonstrated that the histogram data on the value of 2 score grading in dogs with pancreatitis showed a significant difference from normal findings. The histogram confirmed that dogs with pancreatitis have lower mean tissue stiffness that can increase the possibility to predict the severity of pancreatitis.

DISCUSSION

In this study, we evaluated the agreement between Vcheck cPL Rapid test and pancreatic ultrasonography in 22 client-owned dogs with suspected acute pancreatitis. The result of this study is that Vcheck cPL Rapid test and pancreatic ultrasonography have a moderate agreement (weighted kappa: 0.71), thus it indicates that clinicians should not use only specific pancreatic lipase or ultrasonography to investigate acute pancreatitis but should use both of them together, as previously reported [11].

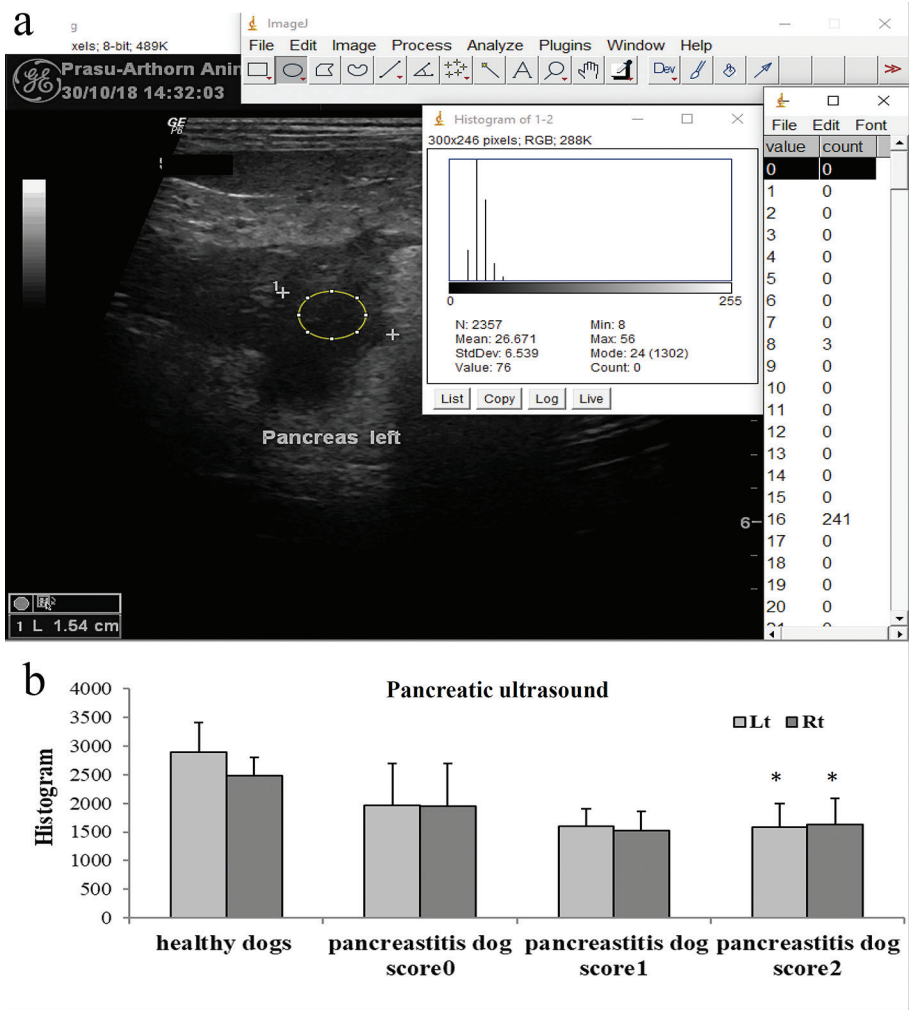


Figure 4. Image J software with the image and the analysis histogram of pancreatic ultrasound (a) the mean histogram in dog groups (b) The data are expressed as the mean±SD (n=11-15). * Significant difference from the healthy dog.

Vcheck cPL Rapid test still did not have any previous research supporting the diagnosis results except the company claim that Vcheck cPL Rapid test using Europium fluorescent is more accurate than general fluorescent particles and there was the comparison to ELISA which is the most reliable diagnostic tool for canine acute pancreatitis found that Vcheck cPL Rapid test results were in high correlation with ELISA, the coefficient of determination value was 0.966 [7].

Pancreatitis is ultrasonographically visible because it is followed by changes in echogenicity and echostructure of the pancreas however its sensitivity varies depending

on the skill of the operator and degree of inflammation which is more visible in severe cases than mild ones. In our study, all images were evaluated by 3 radiologists that were blinded to the Vcheck cPL results, the history, physical examination findings, and clinic pathological data. This approach can be considered both an advantage and disadvantage. Ultrasonographic grading results that the expert majority uses can eliminate the effect of subjective results from a single interpreter which was published in the previous studies [11]. On the other hand, the results highly depend on the skill and experience of each ultrasonographer and can be affected by interobserver variability on interpretation.

By comparing the results of Vcheck cPL Rapid test and results of pancreatic ultrasonography by using weighted kappa coefficient (k) the correlation between two diagnostic methods was assessed in order to determine whether they should be used individually or together. Therefore, a prompt and correct diagnosis facilitates early therapy, which improves the chances of survival. However, it was not possible to determine which procedure is more effective in the diagnostics of acute pancreatitis in dogs. The moderate agreement noted in our study is similar to the previously reported data; they used Spearman's rank correlation coefficients indicating the abdominal ultrasonography should not be the only procedure in the diagnostics of pancreatitis in dogs [11].

The diagnosis of canine pancreatitis is still challenging. Complete blood count and serum biochemistry should be performed in suspected cases although these blood profiles are not specific for pancreatitis. Serum canine trypsin-like immunoreactivity (cTLI) which measures trypsinogen is the other indicator of acute pancreatitis. However, its sensitivity is low due to the short half-life of trypsinogen in the serum, although it is exclusively of pancreatic origin. Serum amylase and lipase activities have also low sensitivity and specificity because they can be synthesized by many tissues such as gastric mucosa, hepatic parenchyma and others which are not specific to pancreas origin [12]. Our study indicated that serum amylase and lipase did not correlate to Vcheck cPL Rapid test and ultrasonography score as shown in the supplement data. Although serum cholesterol and triglyceride concentrations related to lipid metabolism, most dogs with pancreatitis more than 70 % still had serum triglyceride and cholesterol concentrations within reference intervals [13] which is similar to our data. There are 60% and 66.67% of serum cholesterol and triglyceride concentrations respectively that are still within the normal range while both of Vcheck cPL Rapid test and ultrasonography scored 2 as shown in the supplement data.

Abdominal radiography is less useful but can exclude other diseases that may cause similar clinical signs of pancreatitis, while computed tomography is not common because of the anesthesia risks and the high cost for diagnosis [1]. The use of endoscopic ultrasound increases the sensitivity, but is not generally available for veterinarian patients [14]. Histopathology from biopsy remains the gold standard for the diagnosis of pancreatitis however, it is rarely performed due to its invasive and

limitations in live dogs, including the potential to miss localized lesions or subclinical pancreatitis [11].

Histograms were used to evaluate the gray scale in the region of interest for differentiating between the normal and abnormal lesion in humans and dogs [15,16]. In our study the histogram analyses of normal pancreases were significantly different from dogs with pancreatitis. In addition, the histogram data on the value of 2 score grading in dogs with pancreatitis showed a significant difference from normal findings. The histogram confirmed that dogs with pancreatitis have lower mean tissue stiffness that can increase the possibility to predict the severity of pancreatitis. On the other hand, the higher mean tissue stiffness may indicate the absence of lesions or inflammation.

This study had some limitations such as the low number of samples, variation of breeds and the diagnostic sensitivity which depends on the skill and experience of radiologists and greatly affects the consistency of the diagnostic results. The low number of samples could lead to bias in the statistical analysis results. All of this can affect the evaluation of the echostructure in dogs with pancreatitis. In addition, ultrasonography examinations were performed by 3 veterinary radiologists that may impact the data by interobserver variation.

In further studies, increasing the sample size in order to decrease the bias in the statistical analysis of the results is recommended. The authors suggest that evaluation of the agreement between cPL rapid test, ultrasonography and pancreatic biopsy, which is the gold standard, should be performed to compare sensitivity and specificity of them all.

CONCLUSIONS

This study shows that the correlation of Vcheck cPL Rapid test and pancreatic ultrasonography in dogs with suspected acute pancreatitis is in moderate agreement by 0.71 weighted kappa coefficient values which means that both methods should be used in the diagnostics of this pathological condition. Besides that, quantitative ultrasound assessment provides an opportunity to distinguish between normal pancreatic structure and acute pancreatitis.

Acknowledgments

This study was financially supported by a grant of the Faculty of Veterinary Science, Mahidol University. Authors would like to thank Assot. Prof. Dr. Anuwat Wiratsudakul and Asst. Prof. Dr. Sarin Suwanpakdee for statistical advice and also thank Dr. Krittin Chuaychoo for helping ultrasound scan. Moreover, gratefully acknowledge Prasuarthon animal hospital, Mahidol University for supporting the facilities and the veterinarian in Prasuarthon animal hospital who assisted with this project.

Authors' contributions

SH carried out the design of the study, participated in the sequence alignment and drafted the manuscript. PY conceived of the study, the statistical analysis and participated in its design and coordination and helped to draft the manuscript. VI, SN, and SS carried out the experiment and performed the statistical analysis. PJ participated to ultrasound scan. All authors read and approved the final manuscript.

Declaration of conflicting interests

The authors declared no potential conflicts of interest with respect to the research, authorship, and/or publication of this article.


Statement of Informed Consent


The owner understood procedure and agrees that results related to investigation or treatment of their companion animals, could be published in Scientific Journal Acta Veterinaria-Beograd.

Ethical Statement


The animal study was reviewed and approved by the Animal Care and Use Committee of the Faculty of Veterinary Science, Mahidol University, Thailand (MUVS-2018-06-25). All owners of the patients enrolled in the study signed an informed consent agreement.


ORCID iDs


Somkiat Huajiantug  <https://orcid.org/0000-0002-1833-1567>

Paranee Yatmark  <https://orcid.org/0000-0002-0017-4081>

Vitchayarat Itthichaiyasan  <https://orcid.org/0009-0009-5524-2801>

Sarunya Nuaengsri  <https://orcid.org/0009-0008-0387-4500>

Satinee Srithip  <https://orcid.org/0009-0000-8779-8585>

Prukka Julapanthong  <https://orcid.org/0009-0008-3787-2458>

REFERENCES

1. Van den Bossche I, Paepe D, Saunders J, Hesta M, Daminet S: Acute pancreatitis in dogs and cats: medical imaging, biopsy, treatment and prognosis. *Vlaams Diergeneeskundig Tijdschrift* 2010, 79(2):99-108.
2. Watson PJ, Roulois AJA, Scase T, Johnston PEJ, Thompson H, Herrtage ME: Prevalence and breed distribution of chronic pancreatitis at post-mortem examination in first-opinion dogs. *J Small Anim Pract* 2007, 48(11):609-618.
3. Holm JL, Chan DL, Rozanski EA: Acute pancreatitis in dogs. *J Vet Emerg Crit Care* 2003, 13 (4):201-213.
4. Haworth MD, Hosgood G, Swindells KL, Mansfield CS: Diagnostic accuracy of the SNAP and Spec canine pancreatic lipase tests for pancreatitis in dogs presenting with clinical signs of acute abdominal disease. *J Vet Emerg Crit Care* 2014, 24(2):135-43.

5. Cridge H, Twedt DC, Marolf AJ, Sharkey LC, Steiner JM: Advances in the diagnosis of acute pancreatitis in dogs. *J Vet Intern Med.* 2021, 35(6):2572-2587.
6. IDEXX Laboratories, Inc. SNAP cPL test reference laboratory accuracy pet-side [pamphlet]. IDEXX Laboratories, Inc; 2019.
7. BIONOTE Inc. Vcheck cPL Pancreatitis diagnostic marker and Canine pancrease-specific lipase [pamphlet]. BIONOTE Inc; 2019.
8. Larson MM. Imaging of the normal pancreas and pancreatic disease [Internet]. Semantic Scholar. 2013. Available from: <https://www.delawarevalleyacademyvm.org/pdfs/apr13/9Imagingpancreas.pdf>
9. Ripollés T, Martínez MJ, López E, Castelló I, Delgado F: Contrast-enhanced ultrasound in the staging of acute pancreatitis. *Eur Radiol* 2010, 20(10):2518-2523.
10. Beck APA, Araujo JE, Leslie AT, Camano L, Moron AF: Assessment of fetal lung maturity by ultrasound: Objective study using gray-scale histogram. *J Matern Fetal Neonatal Med* 2015, 28:617–622.
11. Cridge H, Sullivant AM, Wills RW, Lee AM: Association between abdominal ultrasound findings, the specific canine pancreatic lipase assay, clinical severity indices, and clinical diagnosis in dogs with pancreatitis. *J Vet Intern Med* 2020, 34(2):636-643.
12. Xenoulis PG. Diagnosis of pancreatitis in dogs and cats. *J Small Anim Pract* 2015, 56(1):13-26.
13. Xenoulis PG, Cammarata PJ, Walzem RL, Suchodolski JS, Steiner JM. Serum triglyceride and cholesterol concentrations and lipoprotein profiles in dogs with naturally occurring pancreatitis and healthy control dogs. *J Vet Intern Med* 2020, 34(2):644-652.
14. Watson P. Pancreatitis in the dog: dealing with a spectrum of disease. In *Practice* 2004, 26(2):64-77.
15. Landoni V, Francione V, Marzi S, Pasciuti K, Ferrante F, Saracca E, Pedrini M, Strigari L, Crecco M, Di Nallo A: Quantitative analysis of elastography images in the detection of breast cancer. *Eur J Radiol* 2012, 81(7):1527–1531.
16. Huaijantug S, Yatmark P, Phophug P, Worapakdee M, Phutrakul A, Julapanthong P, Chuaychoo K. Quantitative ultrasound elastography and serum ferritin level in dogs with liver tumors. *J Adv Vet Anim Res* 2020, 7(4):575-584.

KVANTITATIVNA ULTRASONOGRAFIJA PANKREASA I Vcheck cPL BRZI TEST KOD PSA SA SUMNJOM NA AKUTNI PANKREATITIS

Somkiat HUAIJANTUG, Paranee YATMARK, Vitchayarat ITTHICHAIYASAN, Sarunya NUAENGSR, Satinee SRITHIP, Pruksa JULAPANTHONG

Cilj ovog istraživanja bio je da se proceni važnost kvantitativne ultrasonografije u dijagnostici akutnog pankreatitisa kod pasa, kao i da se ispita korelacija između rezultata ultrazvučnog pregleda i Vcheck cPL brzog testa kod pasa sa sumnjom na akutni pankreatitis. U istraživanje je uključeno ukupno 37 pasa – 15 zdravih pasa i 22 psa sa gastrointestinalnim kliničkim znacima koji su ispunjavali najmanje 1 od 3 kriterijuma

(povraćanje, kranijalni bol u abdomenu i žutica). Serum je uzet radi procene nivoa cPL brzim testom Vcheck cPL. Rezultat 0 implicira da je rezultat Vcheck cPL Rapid testa manji od 200 ng/ml. Rezultat 1 implicira Vcheck cPL Rapid rezultat testa između 200 i 400 ng/ml, a rezultat 2 više od 400 ng/ml.

Ultrazvučni pregled je urađen kod svih pasa kako bi se ispitale lezije pankreasa u roku od 48 sati i procenio nivo pankreatitisa rezultatom od 0 do 2. Kriterijumi za pankreatitis na ultrazvučnim slikama uključivali su povećanje ili nepravilnost pankreasa, hipohogena područja pankreasa i hiperehogenost mezenterijuma koji okružuje pankreas. Ultrazvučna procena pankreatitisa podrazumevala je: skor 0 kada nijedan od kriterijuma nije bio prisutan. Skor 1 kada su bila prisutna 1-2 od 3 kriterijuma i skor 2 kada su bila prisutna sva 3 kriterijuma. Ispitivana je korelacija između Vcheck cPL Rapid testa i ultrasonografije pankreasa. Rezultati pokazuju da je slaganje Vcheck cPL Rapid testa i ultrasonografije pankreasa imalo kapa vrednosti od 0,71 koje su u “umerenom” opsegu slaganja. To znači da bi se i Vcheck cPL Rapid test i ultrazvuk trebali koristiti u dijagnostici akutnog pankreatitisa u svakodnevnoj kliničkoj praksi. Osim toga, kvantitativna ultrazvučna procena može biti od pomoći u razlikovanju akutnog pankreatitisa od normalnog pankreasa.