

PATHOMORPHOLOGICAL ALTERATIONS AND DEGREE OF REPARATORY PROCESSES IN THE LIVER OF BROILERS TREATED WITH T-2 TOXIN

ŠEFER D, KNEŽEVIĆ MILIJANA, SINOVEC SNEŽANA and SINOVEC Z

Faculty of Veterinary Medicine, Belgrade

(Received 11. November 2002)

The 42-day long trial was performed on a total of 48 Hybro broilers divided into four groups. After a 14 day pre-experimental period, the experimental groups were treated daily with T-2 toxin at 0.02 mg/kg BW for 7, 14 or 21 days respectively and a mixture of ethanol and physiological saline was administered to the control group of birds. Liver samples were taken after the period of toxin administration and the remaining birds from the control and experimental groups were normally fed and watered without toxin application until the end of the trial when liver samples were taken again.

Histogenetic development of dystrophic and dyscyclic changes were found in the livers of the treated broilers. Morphological alterations of the liver were diverse in character, intensity and spread depending on the duration of exposure of broilers to the adverse effects of T-2 toxin, as well as the total quantity of toxin applied. The degree of the reparation varied depending on the duration of exposure to toxin, as well as the resting period. Evident reversible processes were found after short term exposure followed by a long resting period, while regeneration processes were not pronounced after chronic poisoning followed by a short resting period.

Key words: poultry T-2 toxin, pathomorphological alterations, reparatory processes

INTRODUCTION

Trichothecens are highly toxic compounds commonly produced as secondary metabolites by *Fusarium* species (Bamburg *et al.*, 1968). One of the most toxic and abundant trichothecene mycotoxins is the T-2 toxin (3-hydroxy-4b, 15-diacetoxy-8-(3-methylbutyryloxy-12,13-epoxy-trichothec-9-ene) and it has been identified in mouldy feed but naturally contaminated feeds generally contain small amounts of T-2 toxin (0.17-2.40 ppm). (Bata *et al.*, 1983; Duletić and Muntanola, 1989).

In recent years T-2 toxin has drawn considerable attention due to its pronounced cytotoxic effects both in animals and humans. It has been found that T-2 toxin provokes pathomorphological alterations in the liver, digestive tract, kidneys, bone marrow, skin and lungs (Uraguchi and Yamazaki, 1978), while other

authors (Buck and Osweiler, 1976; Wyllie and Morehouse, 1978; Humphreys, 1988) also noted the alterations in heart, gallbladder and bile ducts, reproductive organs, spleen and haemotopoietic organs.

Taking into consideration that the liver represents the central point of detoxification of mycotoxins, as well as that the main way of secretion is through the bile (Chi *et al.*, 1978) it is logical to expect that the most pronounced alterations would be in the liver. It is considered (Kurmanov, 1978) that pathomorphological alterations in some species are very similar, but poultry and especially their progeny are most susceptible to the adverse effects of T-2 toxin. Generally observed, it could be concluded that T-2 toxin provokes hemorrhagic diathesis as well as dystrophic and necrotic changes in poultry livers (Vengušt *et al.*, 1988; Hoerr *et al.*, 1981; Hoerr *et al.*, 1982a; Humphreys, 1988). Due to prolonged intake of T-2 toxin, liver alterations were reported to be widespread and well developed in intensity, so that, besides the previously mentioned, there can be focuses of necrosis (Kurmanov, 1978; Hoerr *et al.*, 1982a; Hoerr *et al.*, 1982b) and dominant findings were diffusely disseminated alterations in the portobiliary area (Hoerr *et al.*, 1981).

Because of the health hazards posed by T-2 toxin and especially because of the reports that trichothecene toxins have been used in chemical warfare in South Asia and Afghanistan (Ciegler, 1986; Kadivar and Adams, 1991), it is important to explore all of its toxic effects. Although there is a very extensive literature data concerning pathomorphological alterations of liver caused by T-2 toxin, the degree of reparation process has not been described. The primary objective of this study was not only to investigate the pathomorphological alterations of liver, but to assess the possible sanation process after the removal of causative agents.

MATERIALS AND METHODS

Animals. Hybro broilers were obtained from a commercial hatchery. The trial was performed on 48 day-old chickens, which were housed in wire floor battery brooders. Standard light dark cycle, temperature and moisture conditions were maintained throughout the trial.

Experimental design. After a 14 day long pre-experimental period, the broilers were submitted to the trial and divided into three experimental groups (A, B, D) and one control group (C). The experimental groups were orally treated daily with T-2 toxin at 0.02 mg/kg BW for 7, 14 or 21 days respectively and a mixture of ethanol and physiological saline was administered to the control group of birds. Some birds from the control group were killed successively at seven day intervals, and six birds from the experimental groups after the end of the respective treatment. The remaining birds from all groups were kept without toxin administration until 42nd day, when they were also sacrificed.

Toxin preparation. T-2 toxin produced by *Fusarium sporotrichioides*, kept on liquid media according to Betina (1984), was used for extraction and further refined in the usual way (Bočarov-Stančić and Munatanola-Cvetković, 1989; Bočarov-Stančić *et al.*, 1986). Thin layer chromatography was used for determination of T-2 toxin purity (AOAC, 1980). The degree of purity was 86% compared with the

commercial remedy (99.6% pure). According to Chi *et al.* (1977) the pure, medium lethal dose (LD₅₀) of T-2 toxin is taken as 5 mg T-2/kg BW.

Sample collection. Liver samples were taken after the period of toxin administration and the remaining birds from the control and experimental groups were normally fed and watered without toxin application until the end of the trial (42nd day), when liver samples were taken again. Immediately after sacrifice a detailed macroscopic examination was carried out. In the shortest possible period samples of liver were taken for histological investigations. Liver samples were fixed in 10% neutral formalin and absolute alcohol, embedded in paraffin, sections of 5-8 µm thickness cut and stained using the standard hematoxylin eosin method (Scheur and Chalk, 1986).

RESULTS AND DISCUSSION

No pathomorphological alterations that would point to changes in the normal morphological architecture of liver were found either in the control or experimental groups of broilers. Macroscopic changes in liver have been found in affected or dead broilers during experimental or spontaneous T-2 toxicoses (Hoerr *et al.*, 1982a, Kurmanov, 1978; Humphreys, 1988), but it has to be emphasised that these authors used significantly higher doses of T-2 toxin than the doses in our trial which correspond more to the possible field cases. Although many authors (Kosuri *et al.*, 1971; Smalley, 1973; Carlton and Szczech, 1978; Joffe and Yagen, 1977) detected of hemorrhage of different intensity, from ecchymosis to confluent hemorrhages, our data agreed could be made with Marassas *et al.* (1969) and Weaver *et al.* (1978) who observed no macroscopic changes after prolonged exposure of animals to low doses of T-2 toxin, as well as with Patterson *et al.* (1979) who failed to induce the hemorrhagic syndrome.

Diffuse fatty infiltration and degeneration could be noticed in the liver samples from the short term treated broilers. Only rare hepatocytes were intact, while most of them had unclear borders with cytoplasm filled with different numbers of droplets. The center of lobules could be hardly seen, while Kiernans areas were easily noticeable at the periphery. Besides hepatocytes with preserved integrity and granulated cytoplasm, there were also some cells transformed into an amorphous mass consisting of fatty substance and lumpy detritus of other cell structures (Fig 1).

More prolonged treatment of the broilers caused diffusely distributed cells with increased volume and transparent cytoplasm. In altered areas some hepatocytes could be seen without nucleus along with Kupfer cell activation. Some hepatocytes were destroyed and transformed into a tiny eosinophilic detritus. Moreover, tiny hemorrhages were present, while hyperplasia of bile duct epithelium was noticeable in the Kiernans area (Fig. 2)

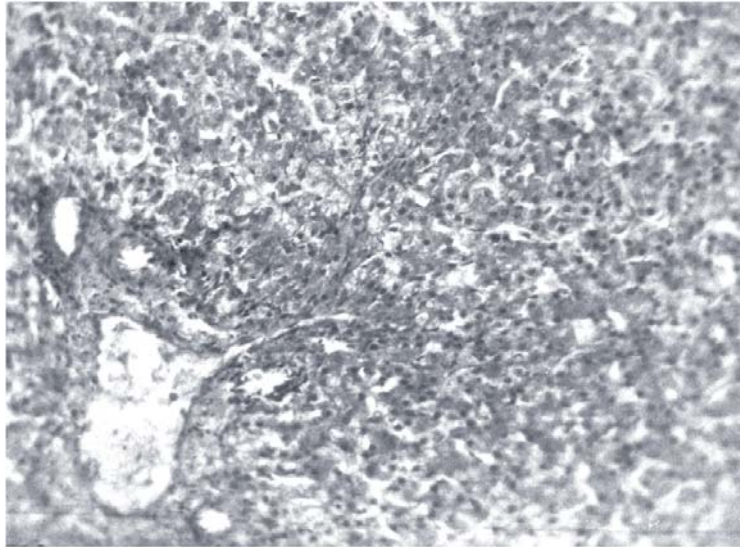


Figure 1. Diffuse fatty infiltration, degeneration and micronecrosis of a broiler liver after 7 days treatment with T-2 toxin. HE. 200x

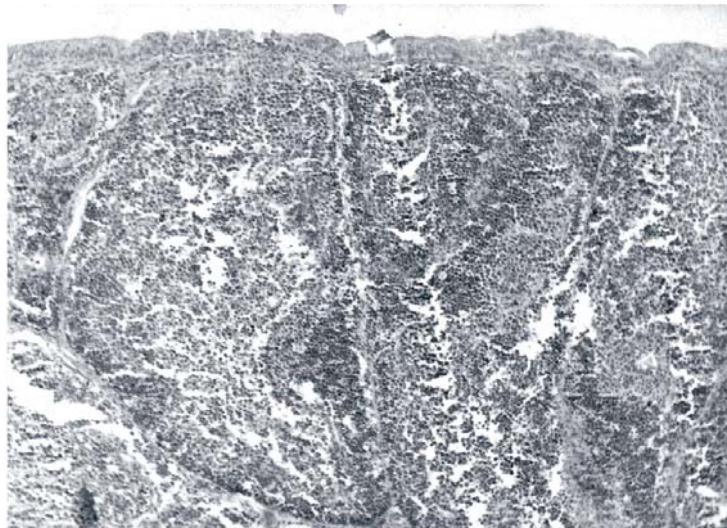


Figure 2. Hyperplasia of bile duct epithelium, and tiny hemorrhages in the liver of a broiler after 14 days treatment with T-2 toxin. HE. 200x

Alteration in the portobiliary region was dominant in the liver samples of the long term treated broilers. Rough connective tissues entered between hepatocytes in the form of strips indicating a interlobular fibrosis. Fatty changes in hepatocytes were still present, but had a focal character.

The character, intensity and spread of the liver alterations were diverse depending on the duration of broiler exposure to the adverse effects of T-2 toxin, as well as the total quantity of applied toxin (Schiefer and Hancock, 1984). After 7-days treatment, some alterations occurred which, according to the intensity and spread, could be described as weak and limited. The dominant findings were degenerative changes with focal and infrequent micronecrosis. It was characteristic that the findings were not constant, which could be connected with individual variations in susceptibility to T-2 toxin (Uraguchi and Yamazaki, 1978). With regard to the previous group, alterations were more intense and spread over wider areas of the liver after 14-days treatment. Besides the fatty degeneration of hepatocytes, focuses of necroses could be noticed in the Kupfer cell region, as well as tiny hemorrhages (Vengušt *et al.*, 1988; Hoerr *et al.*, 1981). The hyperplasia and bile duct necrosis should be emphasized (Hoerr *et al.*, 1982; Hoerr *et al.*, 1982b) as qualitatively different findings. After 21-days treatment, the liver alterations developed in intensity, so that, besides those previously mentioned, focuses of true necrosis could be seen (Kurmanov, 1978; Hoerr *et al.*, 1982a; Hoerr *et al.*, 1982b) as well as fibrous changes diffusely spread in the portobiliary area (Hoerr *et al.*, 1981).

In liver samples from the broilers short term treated with T-2 toxin and sacrificed at the end of the trial, only rare diffuse fatty infiltration of hepatocytes along with weak MMS activation was observed, while the greatest number of cells were intact. A longer period of treatment followed by a short resting period made the repair process slower and weaker. Changes in parenchyma and intrahepatic bile ducts, as well as connective tissue of the portal area were still noticeable. The connective tissues was hyalinized and plenty of bile ducts were incorporated in them. Blood vessels were thicker with fragmentation of tunica media in some cases. Besides the fatty changes, focal necrotic areas, clearly distinct from the surrounding tissues, were noticeable. In the liver samples of the broilers with the longest treatment period and the shortest resting period alterations were more intense in the structure of the Kiernans area. These changes were manifested through signs of extensive interlobular fibrosis (Fig. 3) along with the occurrence of a small number of wide connective tissues strips irregularly inserted between fatty transformed cells. The described strips contain only a few cell elements.

The degree of the reparatory processes varied depending on the duration of exposure to toxin, as well as the resting period. After short term exposure and a 21-day rest period reversible processes were pronounced, so that most of hepatocytes were intact and only sparse diffuse fatty infiltration of hepatocytes, along with weak RNS activation could be seen in the liver. The alterations that occurred after longer exposure and a shorter resting period were restored only partially. Diffuse fatty infiltration was still noticeable along with the presence of real focuses of necrosis and hyalinised blood vessels. The dominant findings in connective tissues in the parenchyma pointed to a certain degree of sanation. After chronic poisoning followed by a short resting period regeneration processes were not pro-

nounced. The dominant fat accumulation in hepatocytes and extensive interlobular fibrosis appearing as a substitution for necrotic cells indicated the beginning of cirrhosis (Robins and Kumar, 1987).

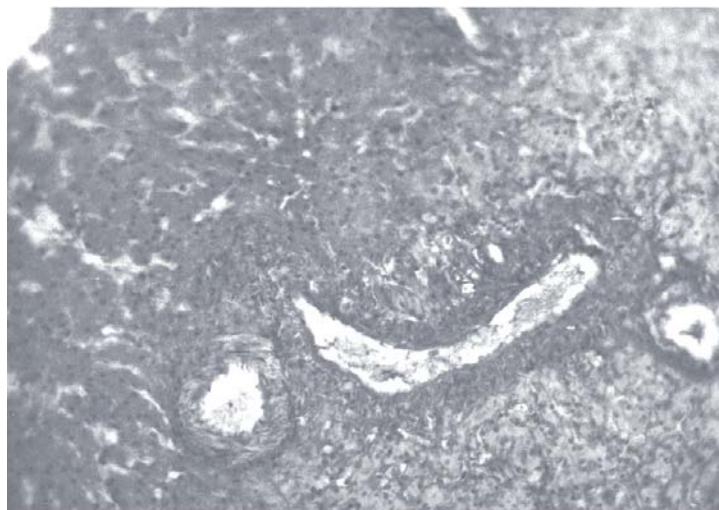


Figure 3. Extensive interlobular fibrosis with focal fatty change in the liver of a broiler after 21 days treatment with T-2 toxin. HE. 100x

The obtained results confirm that T-2 toxin provokes dystrophic and necrotic changes in poultry liver (Vengušt *et al.*, 1988; Hoerr *et al.*, 1981; Hoerr *et al.*, 1982a; Humphreys, 1988). Due to prolonged intake of T-2 toxin, liver alterations were widespread and developed in intensity, namely, histogenetic development of the dystrophic and dyscyclic changes were found in the livers of the treated broilers. Prolonged feeding of broilers with contaminated feed unavoidably led to poor performance caused by morphological followed by functional disturbance of the liver. Morphological and functional disturbance of the liver develops sooner or later and depends on the duration of broiler exposure to the adverse effect of T-2 toxin, as well as the total quantity of applied toxin. Early detection of the presence of T-2 toxin in feed, as well as excluding it from broiler diets represent methods by which the adverse effects and consequences could be overcome to a certain degree considering the pronounced reparatory processes.

Address for correspondence:
Dr Dragan Šefer
Faculty of Veterinary Medicine,
Bul. JNA 18,
11 000 Belgrade, Serbia & Montenegro

REFERENCES

1. AOAC 1980. Mycotoxins methodology. (Ed: Stoloff. L.) Washington DC.
2. Bamberg JR, Riggs NR, Strong FM, 1968. The structures of toxins from two strains of *Fusarium tricinatum*. *Tetrahedron*, 24:3329-36.
3. Bata A, Vanyi A, Sandor Gabriela, 1983. Metabolization of trichothecene toxins (T-2 toxin and diacetoscirpenol) in embryonated hens egg. *Acta Vet Hung*, 31, 189-92.
4. Betina V, 1984. Mycotoxins-production, isolation, separation and purification. 37-44. Els Pub, Amsterdam.
5. Bočarov-Stančić Aleksandra, Jovanović D, Muntanjola-Cvetković Marija, 1986. Biosinteza DAS i T-2 toksina kod izolata roda *Fusarium* sa poljoprivrednih kultura Jugoslavije. Zbor rad II Simp o mikotoksinima, Sarajevo, 129-45.
6. Bočarov-Stančić Aleksandra, Muntanjola-Cvetković Marija, 1989. Uticaj veštačkog održavanja kultura roda *Fusarium* na njihov toksigeni potencijal. Zbor rad III Simp o mikotoksinima, Sarajevo, 113-131.
7. Buck B.W, Osweiler DG, 1976. Mycotoxins. In: Clinical and diagnostic veterinary toxicology. 2nd ed., 261-270, K&H pub. Comp., Iowa.
8. Carlton WW, Szczech MG, 1978. Mycotoxicoses in laboratory animals. In: Willie DT, Morehouse GL ed: Mycotoxic fungi, mycotoxins, mycotoxicoses. vol. 2., 333-427, MD Inc., New York – Basel.
9. Chi MS, Mirocha CJ, Kurtz HJ, Weaver G, Bates F, Shimoda W, Burmeister HR, 1977. Acute toxicity of T-2 toxin in broiler chicks and laying hens. *Poult Sci*, 56, 103-16.
10. Chi MS, Robison ST, Mirocha CJ, Swanson SP, Shimoda W, 1978. Excretion and tissue distribution of radioactivity from tritium-labeled T-2 toxin in chicks. *Toxicol Appl Pharm*, 45, 391-402.
11. Ciegler A, 1986. Mycotoxins: a new class of chemical weapons. *NBD defence & Tehn Int*, 10, 154-60.
12. Duletić Sonja, Muntanjola-Cvetković Marija, 1989. T-2 toksin u Jugoslaviji: rasprostranjenost, koncentracija i biološka aktivnost. Zbor Rad III Simp o Mikotoksinima, Sarajevo, 9-12.
13. Hoerr FJ, Carlton WW, Yagen B, 1981. Mycotoxicosis caused by single dose of T-2 toxin or diacetoscirpenol in broiler chickens. *Vet Path*, 18, 652-64.
14. Hoerr FJ, Carlton WW, Tuite J, Vesonder RF, Rohwedder WK., Szigeti G, 1982a. Experimental trichothecene mycotoxicosis in broiler chickens by *Fusarium sporotrichiella* var. *sporotrichoides*. *Av Path*, 11, 385-405.
15. Hoerr FJ, Carlton WW, Yagen B, Joffe AZ, 1982b. Mycotoxicosis produced in broiler chickens by multiple doses of either T-2 toxin or diacetoscirpenol. *Av Path*, 11, 369-83.
16. Humphreys DJ, 1988, Mycotoxins. In: Veterinary Toxicology. 3rd ed., 283-311, BT Comp., London.
17. Joffe AZ, Yagen B, 1977, Intoxication produced by *Fusarium poae* and *Fusarium sporotrichoides* on chicks. *Toxicon*, 18, 59-74.
18. Kadivar H, Adams CS, 1991. Treatment of chemical and biological warfare injuries: Insights derived from the 1984 Iraqi attack on Majnoon Island. *Military Medicine*, 156, 171-7.
19. Kosuri NR, Smalley EB, Nichols RE, 1971. Toxicologic studies of *Fusarium tricinatum* (corda). Snyder et Hansen from moldy corn. *Am J Ve. Res*, 32, 1843-50.
20. Kurmanov A, 1978. Fusariotoxicoses in chickens in the USSR. In: Willie DT, Morehouse GL ed: Mycotoxic fungi, mycotoxins, mycotoxicoses. vol. 2., 322-7, MD Inc., New York – Basel.
21. Marasas FO, Bamberg JR, Smalley EB, Strong FM, Ragland WL, Degrupe PE, 1969. Toxic effects on trout, rats and mice of T-2 toxin produced by the fungus *Fusarium* (Cd). *Snd. Et Hans. Toxicol Appl Pharm*, 15, 471-82.
22. Patterson SP, Mathews SG, Shreeve BJ, Roberts BA., McDonald SM, Hayes AW, 1979. The failure of trichothecene mycotoxins and whole cultures of *Fusarium tricinatum* to cause experimental haemorrhagic syndromes in calves and pigs. *Vet Rec*, 105, 252-5.
23. Robins SL, Kumar V, 1987. The liver, the biliary tract and the pancreas. In: Basic Pathology. 4th ed., 564-612. W E Saunders Comp, New York.
24. Sheuer JP, Chalk TB, 1986. Clinical test: Histology. Wolfe Medical Publ. LTD, Netherlands.

25. Schiefer BH, Hancock SD, 1984. Systemic effects of topical application of T-2 toxin in mice. *Toxicol Appl Pharm*, 76, 464-72.
26. Smalley BE, 1973 T-2 toxin. *J Am Vet Med Ass*, 163, 1278-81.
27. Uraguchi K, Yamazaki M, 1978. Toxicology, Biochemistry and Pathology of Mycotoxins. HP, New York.
28. Vengušt A, Zust J, Kabaj Zvonka, Vospernik P, Pestevšek U, 1988. Ispitivanje toksičnosti T-2 toksina na brojlerskim pilićima. III Simpozijum o mikotoksinima. Sarajevo. Poseb Izd Anu BIH LXXXIX, knj 14, 23-9.
29. Weaver CA, Kurtz HJ, Beates FY, Mirocha CJ, Behrens JC, Robinson TS, 1978. Acute and chronic toxicity of T-2 mycotoxin in swine. *Vet Rec*, 103, 531-6.
30. Willie DT, Morehouse GL, 1978. Mycotoxic fungi, mycotoxins, mycotoxicoses. vol. 1., MD Inc., New York – Basel.

PATOHISTOLOŠKE PROMENE I STEPEN SANACIONIH PROCESA U JETRI BROJLERA TRETIRANIH T-2 TOKSINOM

ŠEFER D, KNEŽEVIĆ MILIJANA, SINOVEC SNEŽANA I SINOVEC Z

SADRŽAJ

Ogled je izveden na 48 Hybro brojlera podeljenih u četiri grupe. Eksperimentalne grupe su svakodnevno tretirane T-2 toksinom u količini od 0.02 mg/kg TM tokom 7, 14 ili 21 dana, dok je brojlerima kontrolne grupe aplikovana smeša etanola i fiziološkog rastvora. Uzorci jetre za patohistološka ispitivanja uzeti su nakon završetka tretmana, a preostali brojleri su hranjeni i pojeni bez aplikacije toksina do 42. dana kada su uzorci jetre ponovo uzeti.

U jetri tretiranih brojlera utvrđen je histogenetski razvoj distrofičnih i cikličkih promena. Morfološke alteracije jetre razlikovale su se po karakteru, intenzitetu i raširenosti u zavisnosti od dužine ekspozicije brojlera, kao i od ukupne količine aplikovanog toksina. Stepenn sanacionih procesa zavisio je od dužine ekspozicije brojlera, kao i od vremena oporavka. Reparacioni procesi su izraženi nakon kratkotrajnog delovanja T-2 toksina praćenog dugim periodom oporavka, dok se nakon hroničnog trovanja i kratkog vremena oporavka ne uočavaju regeneracioni procesi.