

ELECTROCARDIOGRAPHIC CHANGES DURING CORONARY STENT PLACEMENT IN SWINE

SIMEONOVA GALINA, DINEV D and ROYDEV R

Trakia University, Faculty of Veterinary Medicine, Stara Zagora, Bulgaria

(Received 21st February 2010)

The ECG changes that occurred during coronary stent placement in healthy swine were investigated in order to clarify the effect of surgical manipulation on the electrical activity of the heart.

The experiment was performed on nine female swine weighing 80 ± 2.3 kg under halothane anaesthesia. Eighteen coronary stents were implanted into both left anterior and right coronary artery of the animals using a guiding catheter and transfemoral approach. Multi parameter patient monitor was used to examine closely the ECG changes during the procedure.

Direct stent implantation was successful in 7 of 9 cases and these animals recovered uneventfully. The first two animals died 7-9 hours after surgery because of thrombosis of the stents. Initially all of the seven investigated animals showed sinus rhythm. During the procedure two of the animals developed ventricular arrhythmias. One type of seen electrocardiographic abnormalities was single ventricular premature complexes (VPCs) appearing with an irregular pattern. The other abnormality observed was bigemina that was preceded by multiple VPCs. These ECG changes occurred when the tip of the catheter was advanced too deep through the aorta and touched the endocardium.

ECG changes during coronary stent placement in healthy swine were closely related to the operative technique, but anesthetic agents may contribute to arrhythmias. 6F angiographic catheters did not cause coronary artery occlusion and myocardial ischemia in 80 kg pigs.

Key words: arrhythmia, coronary stents, ECG, swine

INTRODUCTION

Coronary stents have rapidly expanded and become accepted worldwide for treatment of coronary artery disease. Since their introduction in 1987, intracoronary stents have been used almost routinely in percutaneous coronary revascularization.

Cardiac arrhythmias are not uncommon complication of coronary angioplasty in human and animals (Bourassa and Noble, 1976; Maeda *et al.*,

1992; Stone, 2005; Chen *et al.*, 2008). Many factors, such as size of the catheters (Huang *et al.*, 2002), caliber of the coronary arteries (Huang *et al.*, 2002), osmolarity (Bertrand *et al.*, 2000) or toxicity (Nishimura *et al.*, 1984) of the contrast medium, myocardial ischemia (Horowitz *et al.*, 1979) recanalization of the occluded arteries (Murdock *et al.*, 1985), might contribute to the increase incidence of arrhythmias. According to Huang *et al.* (2002) many patients had transient events such as ST depression, ventricular premature complexes (VPCs), and R on T phenomenon that could predispose to the initiation of ventricular tachycardia or ventricular fibrillation which are life-threatening arrhythmias.

Most of these investigations have been performed on patients with coronary artery disease so the effect of the disease on the ECG changes during coronary stent placement was not eliminated. Moreover, the swine heart anatomy is very similar to the human one, so the swine animal experimental model was considered the most appropriate for application the results to human beings.

The aim of the study was to trace the ECG changes that occurred during coronary stent placement in healthy swine in order to clarify the effect of surgical manipulation on the electrical activity of the heart.

MATERIAL AND METHODS

This study was performed in accordance with the Bulgarian's laws regulating human attitude, care, and use of experimental animals. The experimental protocol was approved by the national ethic committee on animal experimentation.

Nine female pigs weighing 80 ± 2.3 kg were included in the study. Eighteen coronary stents were implanted into both left anterior and right coronary artery of the animals using a guiding catheter and transfemoral approach. A day before the operation each of the animals received atenolol (Atenolol Actavis[®], Actavis, Bulgaria) 25 mg, PO.

Animals were premedicated with intramuscular administration (IM) of acepromazin maleate (Neurotranq[®], Alfasan, Holland) 0.3 mg/kg and anesthetized 20 minutes later with (IV) sodium thiopental (Sandoz GmbH, Austria) 10 mg/kg 5% diluted in 0.9% saline solution. Endotracheal intubation was performed and anesthesia was maintained using Halothane (Zentiva, Czech Republic) 1.5 vol. % in oxygen flow 4 L/min. and semi closed respiratory circuit. Fluid balance was maintained by Ringer's lactate solution given at a rate of 10 mL/kg/h after the auricular vein had been cannulated.

MP1000NT multi parameter patient monitor (Mekics Co., Ltd, Korea) was used to examine closely ECG changes during the procedure. Needle ECG electrodes were attached to the patient's right forelimb, left fore limb, and left hind limb according to the user's instruction manual. The monitor processes and amplifies these signals and presents the ECG waveform on the screen. Lead II was selected to observe different ECG parameters such as P wave, PQ interval, QRS height and width, ST segment, T-wave, and QT interval. ECG records were printed before and during stent placement when the changes were most pronounced. Heart rate (RR interval), hemoglobin oxygen saturation, and

respiratory rate were also monitored. Core body temperature was periodically measured using a mercury thermometer and animals were kept warm with blankets.

An 18G needle was inserted in the right femoral artery by direct piercing of the vessels through the skin. A guide wire 0.038" was used to introduce the 6F sheath to the femoral artery. After a bolus intravenous injection of heparin 5000 IU, a 6F coronary angiography catheter (Vivant® RX PTCA, Cologne, Germany) was passed via femoral introducer into the left anterior descending (LAD) coronary artery. The guiding catheter was used to perform angioscopy with two or three injections, which optimally revealed the vessels. Coronary angioscopy was performed using Ioversol 300 mg I/mL nonionic contrast medium (Optiray®, Covidien, Mansfield, MA) in order to confirm the position of the tip of the catheter in the proximal LAD artery. A portable C-arm fluoroscopy guidance (Siremobil Compact; Siemens, Erlangen, Germany) was used. The ECG changes were considered as contrast-related, if they occurred during or less than 10 seconds after injection.

Immediately after the appropriate positioning, the Vivant® Z stent (PFM AG, Cologne, Germany) was placed in the vessel. The balloon was inflated to attain an optimal angioscopic appearance. Stent diameter was 3.00 mm and stent length was 18.3 mm. The mean pressure of stent deployment was 15.3 atmospheres.

The same was repeated in the right coronary artery (RCA).

Postoperatively each of the experimental animals received acetylsalicylic acid (Acetizal®, Actavis, Bulgaria) 1000 mg, PO daily until the end of live in order to be prevented thrombus formation.

RESULTS

Direct stent implantation was successful in 7 of 9 cases and these animals recovered uneventfully. The first two animals died 7-9 hours after operation. During necropsy a thrombosis of the stents was found. In order to prevent this complication in other cases the dose of heparin was increased from 5 000 to 10 000 IU and postoperatively an antiaggregation agent clopidogrel bisulphate (Clopidogrel®, Actavis, Bulgaria) 450 mg, PO was added to acetylsalicylic acid.

Two of the seven investigated animals showed rhythms that were different from the initially recorded in all animals sinus rhythm (Fig. 1). One electrocardiographic abnormality seen in the sixth animal was a single ventricular premature complexes (VPCs) appearing at an irregular pattern (Fig. 2). The other abnormality observed in the ninth animal was bigemina (Fig. 3), that was preceded by multiple VPCs. These ECG changes occurred when the tip of the catheter was wrongly advanced too deeply through the aorta and touched the endocardium.

First arrhythmia was not treated and faded away spontaneously whereas the second was treated effectively with bolus intravenous injection of lidocaine hydrochloride (Lidocain®, Sopharma, Bulgaria) 1% 16 mL followed by infusion of lidocaine 16 mL in 500 mL saline solution for the next hour.

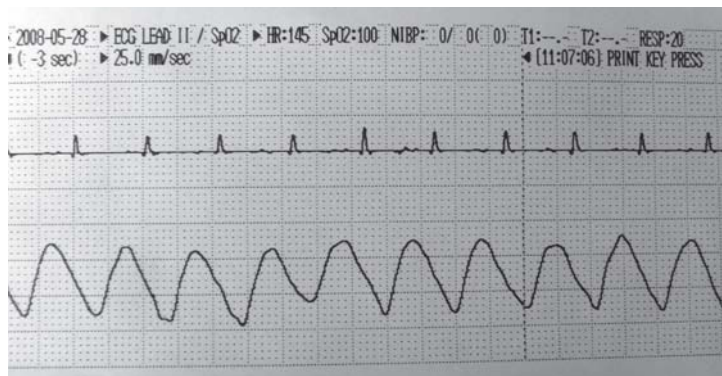


Figure 1. Sinus rhythm in swine recorded before coronary stent placement

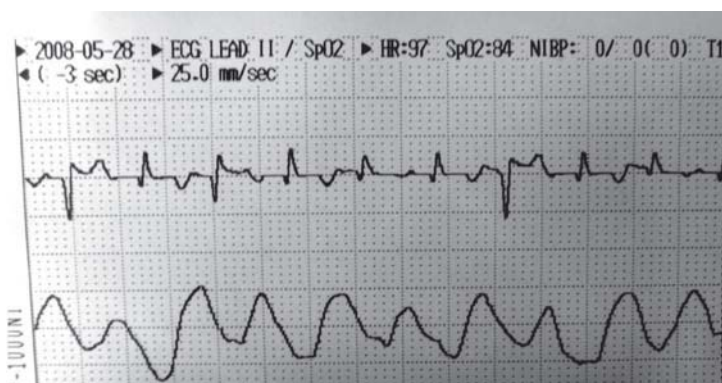


Figure 2. Single ventricular premature complexes – PVC (arrows) appearing at an irregular pattern in swine during coronary stenting

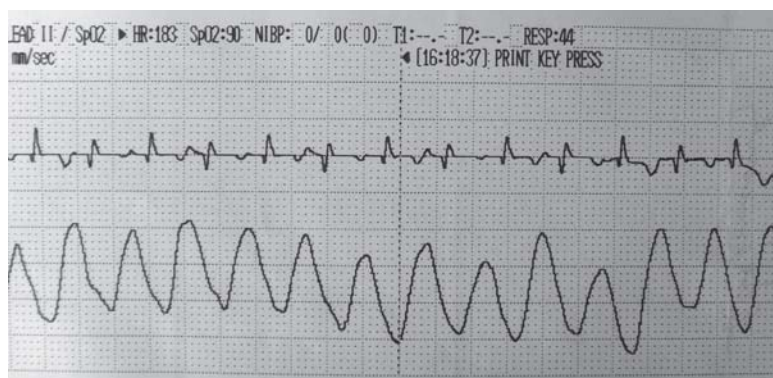


Figure 3. Bigeminy (every second beat was PVC-arrows) in swine that occurred when the tip of the coronary catheter was wrongly advanced too deeply through the aorta and touched the endocardium

All pigs recovered without accidents and no particular events occurred during the next four weeks.

DISCUSSION

Deaths occurred in the experimental study of Nunes *et al.* (1995) after coronary balloon dilation and all of them were attributed to acute thrombosis of ballooned coronary artery, as occurred in the first two pigs of our study. Moreover, Karas *et al.* (1992) concluded that the degree of intimal proliferation in swine appears to be greater after stenting than after balloon injury.

In the study of Huang *et al.* (2002), most of the patients showed ST depression before the onset of ventricular fibrillation (VF), which meant that the initial acute ischemic injury played an important role. Most of the guiding catheters were 7F in patients with VF and this size was very close to the orifice of RCA (2.7mm) that may be occlusive to the artery and contributed to the occurrence of acute ischemia. Our observations did not show any ST or QRS abnormalities that might point to myocardial ischemia. The diameter of the guiding catheter in our experiment was 6F. Durst *et al.* (2007) and Chen *et al.* (2008) consider that smaller size catheters (4 or 5F) can reduce the incidence of catheter vessel occlusion, and it also tends to reduce the volume of contrast material injection, so these contribute mainly to the reduced incidence of complications. Similar are statements of Coelho *et al.* (2004) who claimed that direct stent implantation using 5F guiding catheter and the transradial approach is feasible, safe, and effective, achieving a very low complication rate.

In the studies of Nishimura *et al.* (1984) and Chen *et al.* (2008) ventricular arrhythmias were more frequent during RCA procedures than LCA procedures. The incidence of VF for the right side percutaneous transluminal coronary angioplasty (PTCA) was significantly greater than for the left side (Huang *et al.*, 2002) and it was closely related to the smaller orifice of RCA in the group with VF.

Hypothermia has been reported to be the reason for VF to occur during surgical procedures (Kearns and Murnaghan, 1969), but in our case the core body temperature was maintained within the reference range.

The use of nonionic contrast agents, agents with supplemental calcium added, and agents without calcium ion-sequestering stabilizing agents have been associated with a decreased risk of VF during coronary angiography (Murdock *et al.*, 1985; Missri and Jersaty, 1990; Morris, 1995). We used a nonionic contrast media Optiray 300 with added calcium disodium as a stabilizer at almost two times plasma osmolarity. ECG changes occurred without any connection with contrast injection but were with the manipulation. According to Chen *et al.* (2008) ischemia and contrast medium could make the myocardium more susceptible to ventricular arrhythmias and certain transient event such as improper manipulation might trigger VF attack.

Kumar *et al.* (2007) did not observe any significant complications related to the catheter placement or contrast medium injections during aortic root catheter-directed LAD and RCA angiography in four 40-60 kg pigs using Visipaque®, 5F coronary catheters and femoral approach. However, in their study the pigs have

been pretreated with antiarrhythmic agents such as atenolol and lidocaine infusion during the procedure. Morrison *et al.* (2000) investigated electrocardiographically the cardiotoxic effects of three local anaesthetics applied by injection in the left anterior coronary artery in 40-50 kg pigs. Neither ECG morphology nor heart rate was altered by the placebo injections. The procedure was accomplished using 5F coronary angiography catheter, Iopamiro 370 contrast solution, and femoral approach. In both these studies halothane was not used for anesthesia maintenance.

In our study we used halothane as an anesthetic agent, which might predispose the heart to proarrhythmogenic effects of endogenous catecholamines and thus to exacerbate ventricular arrhythmias triggered by the manipulation.

In conclusion, ECG changes during coronary stent placement in healthy pigs were closely related to the operative technique, but anesthetic agents may contribute to arrhythmias. Touching of the endocardium and halothane should be avoided. 6F angiographic catheters did not cause coronary artery occlusion and myocardial ischemia in 80 kg pigs.

Address for correspondence:
Galina Simeonova
Trakia University
Faculty of Veterinary Medicine
Department of Veterinary Surgery
6000-Stara Zagora, Bulgaria
E-mail: gpsimeonova@uni-sz.bg, galinavet@abv.bg

REFERENCE

1. Bertrand ME, Esplugas E, Piessens J, Rasch W, 2000, Influence of a nonionic iso-osmolar contrast medium (iodixanol) versus an ionic, low-osmolar contrast medium (ioxaglate) on major adverse cardiac events in patients undergoing percutaneous transluminal coronary angioplasty: a multicenter, randomized, double-blind study. Visipaque in percutaneous transluminal coronary angioplasty? VIP Trial Investigators, *Circulation*, 101, 131-6.
2. Bourassa MG, Noble J, 1976, Complication rate of coronary arteriography. A review of 5250 cases studied by a percutaneous femoral technique, *Circulation*, 53, 106-14.
3. Chen J, Gao LJ, Yao M, Chen Jil, 2008, Ventricular arrhythmia onset during diagnostic coronary angiography with a 5F or 4F universal catheter, *Rev Esp Cardiol*, 61, 1092-5.
4. Coelho WM, Jacob JLB, Filho JDA, Frederico SF, Cabbaz IEC, 2004, Direct stent implantation using a 5F guiding catheter and transradial approach, *Arq Bras Cardiol*, 83, 240-2.
5. Durst R, Lotan C, Nassar H, Gotsman M, Mor E, Varshitzki B *et al.*, 2007, Comparison of 4 and 6 French catheters for coronary angiography: Real-world modeling, *Imag Diagn Meth*, 9, 290-3.
6. Horowitz LN, Spear JF, Josephson ME, Kastor JA, Moore EN, 1979, The effect of coronary artery disease on the ventricular fibrillation threshold in man, *Circulation*, 60, 792-7.
7. Huang JL, Ting CT, Chen YT, Chen SA, 2002, Mechanisms of ventricular fibrillation during coronary angioplasty: increased incidence for the small orifice caliber of the right coronary artery, *Int J Cardiol*, 82, 221-8.
8. Karas SP, Gravanis MB, Santoian EC, Robinson KA, Anderberg KA, King 3rd SB, 1992, Coronary intimal proliferation after balloon injury and stenting in swine: an animal model of restenosis, *J Am Coll Cardiol*, 20, 467-74.
9. Kearns JB, Murnaghan MF, 1969, Ventricular fibrillation during hypothermia, *J Physiol*, 51P, 53.

10. Kumar A, Bis KG, Shetty A, Vyas A, Anderson A, Balasubramaniam M et al., 2007, Aortic root catheter-directed coronary CT angiography in swine: coronary enhancement with minimum volume of iodinated contrast material, *Am J Roentgenol*, 188, W415-22.
11. Maeda T, Saikawa T, Niwa H, Kohmatsu K, Shimoyama N, Hara M et al., 1992, QT interval shortening and ST elevation in intracoronary ECG during PTCA, *Clin Cardiol*, 15, 525-8.
12. Missri J, Jeresaty RM, 1990, Ventricular fibrillation during coronary angiography: reduced incidence with nonionic contrast media, *Cathet Cardiovasc Diagn*, 19, 4-7.
13. Morris TW, 1995, A review of coronary arteriography and contrast media induced ventricular fibrillation, *Acta Radiol*, Supplementum, 399, 100-4.
14. Morrison SG, Dominguez JJ, Frascarolo P, Reiz S, 2000, A comparison of the electrocardiographic cardiotoxic effects of racemic bupivacaine, levobupivacaine, and ropivacaine in anesthetized swine, *Anesth Analg*, 90, 1308-14.
15. Murdock DK, Johnson SA, Loeb HS, Scanlon PJ, 1985, Ventricular fibrillation during coronary angiography: reduced incidence in man with contrast media lacking calcium-binding additives, *Cathet Cardiovasc Diagn*, 11, 153-9.
16. Nishimura RA, Holmes DR, McFarland TM, Smith HC, Bove AA, 1984, Ventricular arrhythmias during coronary angiography in patients with angina pectoris or chest pain syndromes, *American J Cardiol*, 53, 1496-9.
17. Nunes GL, Sgoutas DS, Redden RA, Sigman SR, Gravantis MB, King SB, et al., 1995, Combination of vitamins C and E alters the response to coronary balloon injury in the pig, *Arterioscler Thromb Vasc Biol*, 15, 156-65.
18. Stone GW, 2005, Coronary stenting. Complications and the optimal use in adjunctive pharmacology. In: Baim DS, editor, Grossman's Cardiac catheterization, angiography, and interventions, VII ed., Lippincott Williams & Wilkins, 492-543.

ELEKTROKARDIOGRAFSKE PROMENE KOD SVINJA U TOKU POSTAVLJANJA KORONARNOG STENTA

SIMEONOVA GALINA, DINEV D i ROYDEV R

SADRŽAJ

U cilju utvrđivanja efekata hirurške manipulacije na električnu aktivnost srca zdravih svinja praćene su elektrokardiografske promene u toku postavljanja koronarnog stenta. Eksperiment je izveden na devet nazimica prosečne telesne mase od $80 \pm 2,3$ kg podvrgnutih halotanskoj anesteziji. Ukupno je transfemoralnim pristupom postavljeno 18 stentova u levu i desnu koronarnu arteriju upotrebom katetera sa navođenjem. Tokom procedure korišćen je multiparametarski monitoring.

Direktno postavljanje stenta je bilo uspešno u sedam od devet slučajeva i ove životinje su se uspešno oporavile. Prve dve životinje su uginule 7 do 9 časova posle operacije usled tromboze stenta. Na početku je kod svih sedam životinja utvrđen sinusni ritam rada srca, a dve jedinice su imale znake ventikularne aritmije. Dominantna elektrokardiografska abnormalnost se sastojala u pojavi ventrikularnih pred-kompleksa (VPC) koji su se nepravilno pojavljivali. Osim toga utvrđena je

bigeminija kojoj su prethodili višestruki VPC. Ove promene su nastajale kad je vrh katetera, prolazeći kroz aortu dodirivao endokard.

Elektrokardiografske promene tokom postavljanja koronarnog stenta zdravim svinjama su bile povezane sa operativnom tehnikom, ali je pojava aritmije bila u vezi sa primenjenim anestetikom. Angiografski kateteri tipa 6F nisu dovodili do okluzije koronarnih arterija i ishemije miokarda kod svinja telesne mase od 80 kg.