

MEASURING OF MANDIBLE BONE DENSITY IN DOGS USING /DIGITAL RADIOGRAPHY/ RADIOVISIGRAPHY

ILIĆ Dragan^{1*}, STOJANOVIĆ Ljiljana², ANTONIJEVIĆ Djordje^{3,4}, MILUTINOVIĆ-SMILJANIĆ Sanja³, SAVIĆ-STANKOVIĆ Tatjana¹, MILOSAVLJEVIĆ Željko²

¹Dpt. of Restorative Odontology and Endodontics School of Dental Medicine University of Belgrade, Serbia; ²Orthodontic dpt., School of Dental Medicine University of Belgrade, Serbia; ³Dpt. of General and Oral Histology and Embryology School of Dental Medicine University of Belgrade, Serbia;

⁴Laboratory for Atomic Physics, Institute for Nuclear Science "Vinca", University of Belgrade, Serbia.

(Received 08 May, Accepted 24 June 2020)

Radiological diagnostics serves as one of the basic monitoring techniques in veterinary dental practice. The recent up-to-date literature data based on the findings of digital radiology/radiovisiography (RVG) in general dentistry inspired the authors to present its possible use in clinical veterinary dentistry. The digital radiography used in this study was RVG Trophy Radiologie SA 2001 device equipped with software for linear measurements (readings), densitometry, setting of contrast of radiography image, 3D image manipulation, zooming of detail and orientation handling. The aim of the study was to evaluate the bone mineral density of the alveolar part of the lower jaw in seven Scottish terriers. Bone mineral density measurement was performed around the central lower incisors by converting gray scale values into equivalent aluminum thickness (mm Al). The mean bone mineral density was in the range of 4.31-6.20 mm Al with no significant statistical difference between left and right incisors ($p>0.01$). Our results showed that the combination of RVG and aluminum step wedge etalon is a reliable tool to measure bone mineral density around the lower central incisors in dogs. This method can be considered as comfortable for manipulation in everyday use in clinical veterinary practice.

Key words: digital radiography, mandible, morphometry, radiovisiography, densitometry

INTRODUCTION

One of the first who measured the radiological density of the mandible was Richards [1]. His penetrometer measured the radiopacities of tissues (frontal mandibular bone and lips) by the help of aluminium equivalent method and simple step wedge etalon which was made of 94% Al-alloy [1]. Bruhl reported that radiographing (R) of vertebrates, as well as invertebrates, had already been started in 1895, the same year when X

*Corresponding author: e-mail: dr.ilicb@gmail.com

rays were discovered. [2]. Since then, various animal species underwent radiological imaging for anatomical diagnostic purposes. Veterinary radiology progressed parallel to the human one having in mind the specificity of the vertebrate animals' anatomy. Nowadays, in veterinary practice radiovisiography (digital radiology - DR) systems are incorporated in modern R devices and became more than unjustifiably named "accessory diagnostic mean". Indeed, DR is considered an important diagnostic tool especially for emergency cases in veterinary medicine such as fractures of jaws, teeth and temporomandibular joint.

The first investigations of the accuracy and quality of digitally obtained radiographs have been initiated in 1968 [3]. A few years later, investigations were focused on the operator-interactive computer controlled systems capable to perform high-fidelity digitalization of medical images [4]. The digital era in dental radiology began in 1987 when the first DR device called RadioVisioGraphy (RVG) or DR was launched by Trophy Radiologie (Vincennes, France) introducing for the first time a intraoral roentgen-ray imaging sensor. Since then, many researches appeared concerning veterinary diagnostics [5-7]. Soon, the wireless sensor was released (Carestream Dental Co) invented by P. Suni. Having in mind, limited data about 3-D objects gained by conventional R, Francis Mouyen employed fibre optics to decrease the size of the X-ray image allowing its detection by charge-coupled device (CCD), powerful image sensor chip [8]. In this manner, DR eliminates the need for X-ray film and associated toxic chemicals employing a re-usable semiconductor imaging device to capture X-rays. DR significantly improves diagnostics, economics and workflow in dental offices. In that way, the adoption of DR improved animals and environmental health and safety. More recently, the development of sophisticated computer graphical applications has enabled a wide spectrum of new possibilities for the qualitative and quantitative analyses of animal/human studies that were beyond of investigators' reach using conventional R. Nowadays, DR has developed a great superiority exposing many benefits even in veterinary dentistry [9,10]. For example, the use of the intraoral camera [11] with LCD display screen enables dental examinations during ambulance interventions. Concerning the methods for bone density measurement, the most frequent is dual-energy X-ray absorptiometry (DEXA) analysis by RVG images that enables the qualitative measurement of scanned tissue, in many literature articles named as the bone mineral density (BMD) (g/cm^2). For instance, BMD is a useful parameter for scoring of periodontal diseases regardless of etiological factors [12,13].

Although conventional R showed satisfactory results in bone changes in dogs [14,15], RVG becomes more suitable in analysing the dental status of dogs, in general, and it might be a useful tool for monitoring periodontal diseases in permanent teeth. This statement was confirmed by Kyllar *et al.* [16] reporting around 60% of periodontal diseases by the help of RVG cases among urban dogs population and other animals [17,18].

According to the mandibular landmarks Arsic *et al.* (2010) compared the values obtained by sliding calliper-ruler gauging and those obtained by software method of

2-D reconstruction of the lower jaw through computed multislice scan tomography. They recommended the use of a correction factor for calculation of parametric model between indirect morphometry on 2D reconstructions of mandibular and multi-sliced scan tomography [19].

The importance of high precision DR for radiographing in some dogs (hunting dog, shepherd-dog, police dog, guide dog - retriever etc.) is obvious concerning periodontal disease and malocclusions due to their duties and quality of bite force especially in police dogs. The role of a well arranged teeth set is important for neutral occlusion and firm bite (bite force) what veterinary orthodontics might control by the help of DR. Also, to determine the oral health status, condition of dentition in thoroughbred dogs, is very important for cynologist. Considering the degree of periodontal disease is in accordance to the bone pathology resulting in enlarging of lacunar spaces and thinning of alveolar trabeculae in dogs [9]. More specifically, it is to stress the importance of monitoring of crucial factors such as rounding and loss of height of alveolar crest with loss of continuity of the lamina durra and periodontal ligament widening [20].

Due to the lack of extensive literature data regarding the use of digital radiography in veterinary medicine, the aim of this report was to present the application of digital radiography tools for the analysis of the quality of the lower jaw in dogs, specifically, to assess the bone mineral density of the alveolar part around the mandibular central incisors.

MATERIAL AND METHODS

The material was presented by the frontal regions of the lower dentate jaw bone in seven dogs, breed of Scottish terriers (*Canis lupus familiaris*) (six years of age weighing between 5 kg and 7 kg). The radiography in dogs was done upon oral sedation. Trophy Radiologie SA, 2001 SA with accompanying programme (Trophy for Windows software) and CCD-based digital intraoral sensor (RVG-4) (Cedex, France) was applied [21]. The device operated at 60 KV and 7 mA with 0.063 s exposure. The central beam was directed perpendicularly to the CCD sensor toward the uppermost point of the mandibular symphysis. X rays tube head was tipped forward as 15° to the CCD plate to be as much as parallel to the central lower incisors' alveoli. The focus-to-target distance of 20 cm was used. The BMD were analyzed on the digital images an expressed as mean grey scale values using the Trophy software. Software tool for gray scale value reading was applied along A-B line (alveolar part between apex and coronal peak medially of lower central incisors - Fig. 1). Three readings were taken for each dog's bone and for each step of the aluminum wedge etalon. To calculate BMD, a graph was plotted for the logarithm of the thickness of the aluminum step wedge versus the corresponding radiographic density of the step wedge (Fig. 2, 3). BMD of the dogs' alveolar bone was determined by three steps: 1) measuring the gray scale value of central incisor alveolar bone (Trophy for Windows software) (Fig. 4); the BMD was displayed by grey scale value in the range of 0-256 measured by Trophy

digital radiology software; 2) measuring the grey scale values of each step of the aluminum step wedge (0-10) with the help of Trophy for Windows software (Fig. 4); 3) converting the gray scale values of the alveolar ridge into the equivalent aluminum thicknesses (mm Al). SPSS version 20.0 was used to compare the BMD between right and left incisors ($p < 0.05$) (Pair sampled T test).

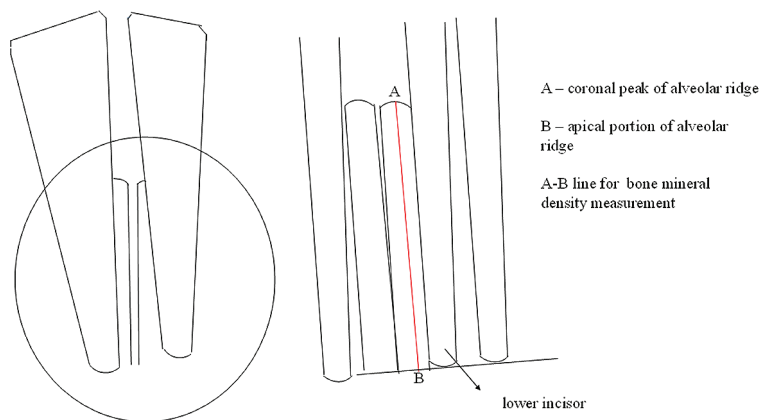


Figure 1. Schematic image of the region of interest, symphyseal region of the mandible, for alveolar ridge measuring with A-B line for bone mineral density measurement

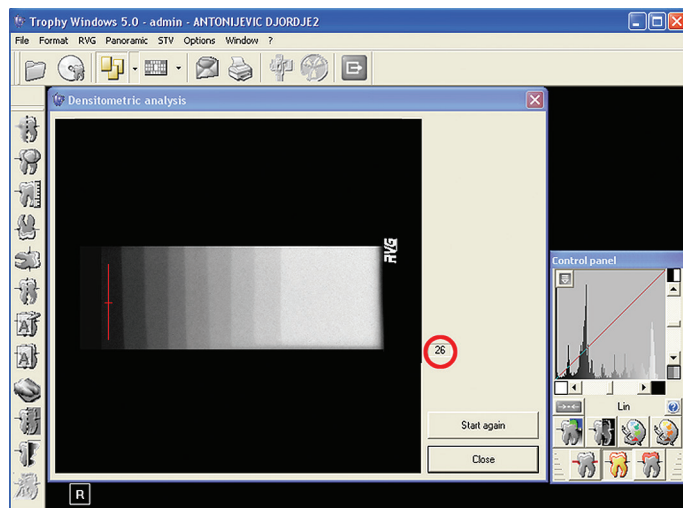


Figure 2. Radiographic image of the aluminum step wedge obtained by Trophy for windows digital radiographic system. Red line indicates the place of the gray scale value measurement (2 mm thickness). The value of the grey scale is encircled in red.

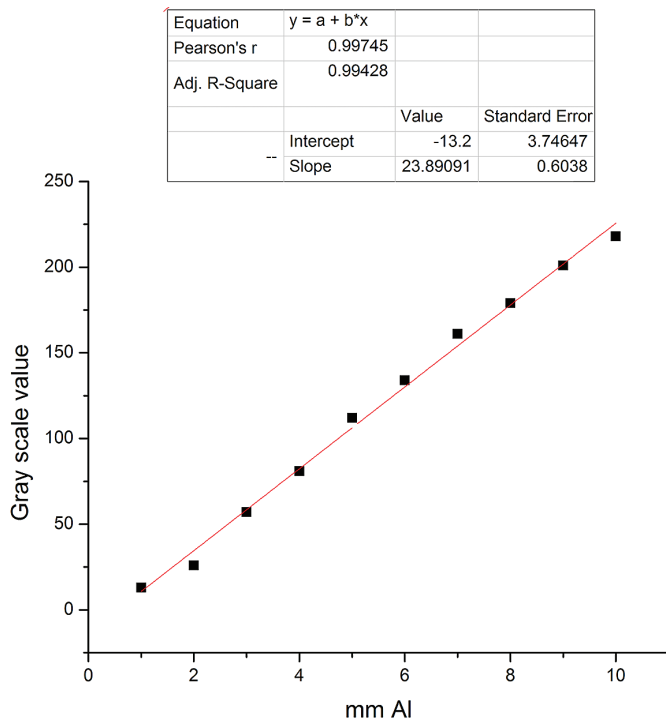


Figure 3. Radiographic density of aluminum step-wedges versus logarithm of step-height (thickness). The gray scale values calculated by aluminum step wedge where plotted against aluminum thickness ($\rho = 0.99$) where slope and intercept were determined.

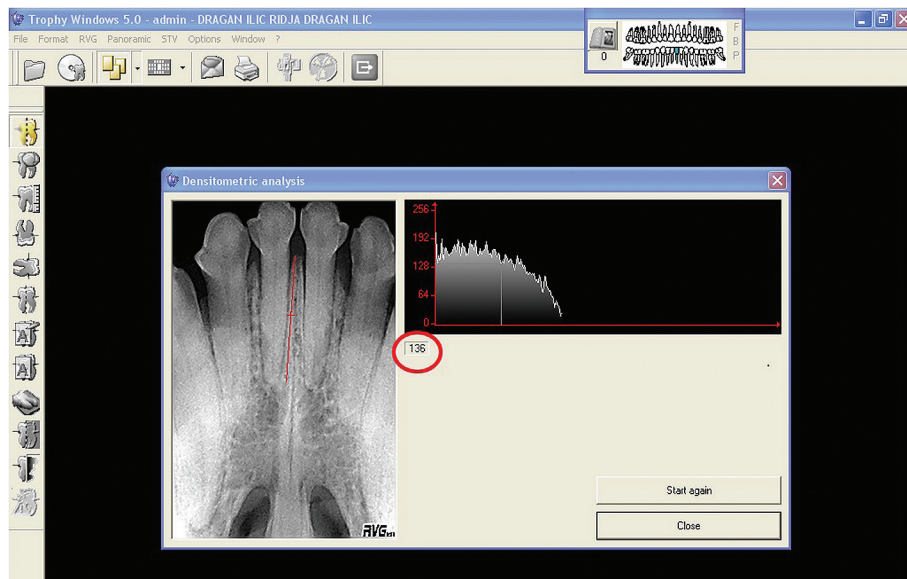


Figure 4. Digital radiography of investigated dog's alveolar ridge. Encircled in red is measured gray scale value. Note the decrease in gray scale value from apical to the coronal part of alveola.

RESULTS AND DISCUSSION

In our study it was noted that there was no difference between the left and right central lower incisors ($p > 0.05$) neither by measuring gray scale values nor by equivalent thickness of aluminum. The obtained gray scale values were in the range of 110-134 while measured BMD was in the range 4.31-6.20 mm Al (Tab. 1). Average gray scale values for the left incisor was 120 ± 10 and for the right incisor 111 ± 15 where no statistical significance was noted ($p > 0.05$). The same results were obtained for BMD values when comparing the left (5.57 ± 0.7 mm Al) and right (5.57 ± 0.4 mm Al) alveolar bone in the region of the incisors ($p > 0.05$). The results obtained by measuring gray scale values are highly correlated with those observed for BMD ($p=0.99$).

Table 1. Bone mineral density of the dogs' lower jaw alveolar bone expressed as mean \pm SD of aluminium thickness

	Left incisor		Right incisor		Mean for both incisors	
	GSSU value	AESU value	GSSU value	AESU value	GSSU value	AESU value
Dog 1	112.0	5.24	126.0	5.82	118.0	5.49
Dog 2	115.0	5.36	113.0	5.28	114.0	5.32
Dog 3	130.0	5.99	133.0	6.11	131.5	6.05
Dog 4	110.0	5.15	90.0	4.31	100.0	4.73
Dog 5	134.0	6.20	130.0	5.99	132.0	6.01
Dog 6	121.0	5.61	125.0	5.78	123.0	5.69
Dog 7	117.0	5.44	123.0	5.70	120.0	5.57
mean \pm SD	123.4 \pm 10	5.57 \pm 0.4	111.4 \pm 15	5.57 \pm 0.6	117.4 \pm 11	5.6 \pm 0.5

Abbreviations: GSSU (gray scale shade unit), AESU (aluminium etalon shade units)

BMD range: 110 -134 GSSU

BMD range: 4.31-6.20 AESU

As osteoporosis has been existing for several decades as one of the leading problem in osteology of animals [22, 23], many technical methods, whether device or biochemically based have been developed. Due to that, the importance of the use of dental radiology is important among the veterinary dental specialist and recognized by the American Board of Veterinary Specialties [24]. In the USA, the number of DR devices is in continuous rise due to the high income. Despite the high cost of DR devices, whether portable or static one, their advantages (prompt radiogram operations, lower exposition) overcome the disadvantages (sharpness, high cost). Having in mind that measuring BMD method is recommended as the reference of International Society for Clinical Densitometry (ISCD) (DEXA of the posterior–anterior spine and the hip) [25], we suggest its possible replacement by DR method owing to less radiation of animals and simple and comfort manipulation. DEXA also calculates fracture risk assessment index and predicts the risk of fracture in the next 10

years as well as trabecular bone score, which evaluates the bone hardness, the degree of malformation of the microarchitecture. The lower values of these parameters, as well as lower BMD, point out the tendency to fracture [26]. Regarding all the before mentioned, the animals could be referred to DEXA scanner in the case of BMD lower than 19 kg/m^2 : old age, absence of a female's menstrual cycle, low intake of vitamin D, renal dysfunction, Cushing syndrome, gastrointestinal diseases, liver malfunction, intake of corticosteroids for more than 3 months [27]. Some authors measured BMD of the calcaneus bone [26] and mandibular body as well as and its angle [28] to access the general skeletal bone mass confirming DEXA as a very reliable method. Although DEXA is very accurate, it requires several mathematical calculations. An interesting improvement in dentistry for measuring BMD in the region of the mandibular second premolar/first molar region/edentulous span was the use of dental panoramic DR equipped with digital densitometry software (Kodak 9000C - 3D Imaging System). One tool of this software allows the measurement between two different points as a linear distance measurement and the readings reveal the average gray scale value at any given point. The same possibility is allowed by the Trophy for Windows Software used in this study [21].

Bone density can be measured using optical densitometry that employs the analysis of retroalveolar radiographs based on the bordering and assessing quadrants within the grid (orthopantomograph). The optical density is measured in the quadrants within the border. This method for BMD assessing was later adopted for digital densitometry devices (DT II, England) [7,29-31]. We applied the same method in Trophy system measure density of lower jaw bones and experienced easiness and comfort of the method.

The first study about osteoporosis in dogs, i.e. BMD, was done by Henrikson *et al.* in 1970 [23] using conventional microradiographs. The authors scanned the lower jaw by radioactive ^{125}I what resulted in a significantly decreased mineral mass. This method is successfully used for many clinical veterinary purposes: osteoporosis [32], dogs ageing phenomenon [33], all-meat diets [34] and in autoimmune diseases [35]. There are also several other methods used in veterinary practice to measure BMD: single photon absorptiometry, dual photon absorptiometry, quantitative ultrasonic osteodensitometry and non-invasive and low-radiated quantitative computerized tomography [36].

The T scores for expressing BMD given by ISCD for average young health are: A) normal: >-1 to $+\infty$; B) osteopenia: -1 to -2.49 ; C) osteoporosis: ≤ -2.5 to $-\infty$ [37]. Since all the dogs were relatively young (5 years on average) and properly fed, we expected to obtain the BMD results as physiological ones. Therefore, obtained BMD value of $\sim 5 \text{ mm Al}$ can be considered as normal. In addition, gray scale values in the range of 90-134 might be labelled as a condition without the presence of osteoporosis. Considering the aforementioned, there is a need to correlate the BMD values found in this study and expressed by thickness of aluminum with T scores used by DEXA method.

The proposed method for calculating BMD at the region of alveolar ridge of dogs' jaws can be considered reliable having in mind that very homogenous data was obtained. The advantage of using DR device is data archiving and easy check-up and follow-up. The significant application of DR might be implemented in veterinary anthropometric and archaeological researches as well, particularly if portable radiovisiography device is available. In addition, it would improve the veterinary surgery during operation where fast decision making is required. In line with this, powerful software programs incorporated in the appropriate DR device will facilitate the procedure.

CONCLUSION

Our results showed that DR and aluminum step wedge etalon can be successfully used to determine BMD in dogs lower jaw. Those statistical differences were found in BMD values between left and right lower jaw alveolar central incisors' regions. It can also be concluded that this method is quick and comfortable for manipulation and should be recommended for everyday use in clinical veterinary practice.

Ethical statement

The whole study was in accordance to the Regulations on Animal Welfare in Veterinary Practice for experiments on the animals, School of Dental Medicine, Belgrade University (protocol number 36/142011 dated from 19.05.2011).

Authors' contributions

ID made an idea for research, participated in experimental protocol and drafting the manuscript. SLj participated in experimental protocol. ĐA participated in result presentation, manuscript design and text proof. MSS participated in result interpretation and text proof. SST participated in result presentation of analysed radiographic image, literature citing and technical support. MŽ participated in literature citing, text corrected and technical support of the manuscript. All authors participated in final proof of the manuscript and necessary corrections.

Declaration of conflicting interests

The author(s) declared no potential conflicts of interest with respect to the research, authorship, and/or publication of this article.

REFERENCES

1. Richards AG: Penetrometer for measuring the radiopacities of tissues. *J D Res.* 1950; 29, 193-209, 696.
2. Spoor FN Jeffrey, F Zonneveld: Uber Verwendung von Rontgenschen X-Strahlen zu palaontologisch-diagnostischen Zwecken *Archiv fur Anatomie und Physiologie* 547–550. In: Using diagnostic radiology in human evolutionary studies. F 1. 1. 1. Spoor, *J Anat* 2000; 197:61–76.
3. Ando S, Nishioka T, Ozawa M, Yamano H, Shinoda K: Computer Analysis of Radiographic Images. *The Journal of Nihon University School of Dentistry.* 1968; 10(2):65–70.
4. Greenleaf JF, Ritman EL, Wood EH, Robb RA, Johnson SA: Dynamic computer-generated displays of data from biplane roentgen angiography for study of the left ventricle. *Ann Biomed Eng.* 1974;2(1):90-105
5. Bidgood WD, Horii S: Introduction to the ACR-NEMADICOM standard. *RadioGhraphicd* 1992;12(2):345-55.
6. Mattoon JS: Digital radiography. *Vet Comp Orthop Traumatol* 2006;19(3):123-32.
7. Ilic DV, Stojanovic L. Application of radiovisigraphy (digital radiology) in dental clinical practice. *Vojnosanit Pregled.* 2012; 69(1):81–4.
8. Mouyen F, Benz C, Sonnabend E, Lodter JP: Presentation and physical evaluation of RadioVisioGraphy. *Oral Surgery, Oral Medicine, Oral Pathology.* 1989; 68(2):238–42.
9. Cedric T: Small Animal Dentistry. In: Radiography, Chapt 4, 83-131. In: Chapt 10 Endodontic therapy. 213-29. Blackwell Publishing. 2006
10. Lyon K: Endodontic therapy in the veterinary patient, In: Holmstrom SE ed. 1998, *Veterinary Clinics of North America, Small Animal Practice.* 1998; 28 (5); 1203-36.
11. Schott TC, Arsalan R, Weimer K: Students' perspectives on the use of digital versus conventional dental impression techniques in orthodontics. *BMC Med Educ.* 2019;19(1):81. doi: 10.1186/s12909-019-1512-3
12. Zang S, Mu R, Chen F, Wei X, Zhu L, Han B, Yu H, Bi B, Chen B, Wang Q, Jin L: Injectable chitosan/ β -glycerophosphate hydrogels with sustained release of BMP-7 and ornidazole in periodontal wound healing of class III furcation defects. *Mater Sci Eng C Mater Biol Appl.* 2019;99:919-928. doi: 10.1016/j.msec.2019.02.024.
13. Bauer AE, Stella J, Lemmons M, Croney CC: Evaluating the validity and reliability of a visual dental scale for detection of periodontal disease (PD) in non-anesthetized dogs (*Canis familiaris*). *PLoS One.* 2018;13(9):e0203930. doi: 10.1371/journal.pone.0203930.
14. Mijuskovic D: Klinička i eksperimentalna ispitivanja reparatornih procesa u apikalnom parodonticijumu posle endodontskih zahvata. *Doktorska disertacija.* 1981, Beograd.
15. Krstic N: Radiolosko pracenje regenerativnih promena na alveolama zuba u odnosu na urođeni nedostatak zuba u pasa. *Magistarska teza,* Beograd, 1992.
16. Kyllar M, Witter K: Prevalence of dental disorders in pet dogs. *Veterinarni Medicina.* 2005; 50(11):496–505.
17. Page RC, Schroeder HE: Periodontitis in man and other animals: A Comparative Review. *S. Karger;* 1982; 208-21.
18. Semedo-Lemsaddek T, Tavares M, Braz BS, Tavares L, Oliveira M: Enterococcal infective endocarditis following periodontal disease in dogs. *PLoS ONE.* 2016; 11(1):e0146860. doi: 10.1371/journal.pone.0146860.

19. Arsić S, Perić P, Stojković M, Ajduković Z: Comparative analysis of linear morphometric parameters of the humane mandibula obtained by direct and indirect measurement. *Vojnosanit Pregl.* 2010; 67(10):839-46.
20. Kurtdede E, Aralan G, Cengiz R, Kiliç Aa, Coşkun Ç, Salmanoğlu B: Evaluation of systemic inflammation parameters in dogs with periodontitis. *Acta Veterinaria-Beograd* 2019; 69(2):218-228.
21. Berthel A, Bonin T, Cadilhon S, Chatellier L, Kaftandjian V, Honorat P, Le Brun A, Maglaive JC, Moreau P, Pettier J, Rebuffel V, Roenelle R: Digital Radiography: Description and User's Guide DIR 2007 - International Symposium on Digital industrial Radiology and Computed Tomography, June 25-27, 2007, Lyon, France
22. Pantelić J, Filipović B, Šošić-Jurjević B, Ajdžanović V, Trifunović S, Medigović I, Milošević V. *Vitex agnus-castus* essential oil affects thyroid c cells and bone metabolism in middle-aged male rats. *Acta Veterinaria-Beograd* 2013; 63(1):23-35.
23. Henrikson P, Lutwak L, Krook L: Fluoride and nutritional osteoporosis: Physiochemical data on bones from an experimental study in dogs. *J Nutr* 1970, 100:631.
24. National Research Council, Policy and Global Affairs, Division on Earth and Life Studies: Academic Veterinary Medicine in Workforce Needs in Veterinary Washington DC: The National Academic Press 161-189. www.nap.edu
25. Cole RE: Improving clinical decisions for women at risk of osteoporosis: dual-femur bone mineral density testing. *J Am Osteopath Assoc* 2008; 108 (6): 289-95.
26. Taneja P, Meshramkar R, Gutta KS: Assessment of bone mineral density in pre- and post-menopausal woman using densitometric software: A pilot study. *Journal of Interdisciplinary Dentistry* 2015; 5(3):125-30.
27. Corbee RJ. Nutrition and the skeletal health of dogs and cats. Doktorska disertacija Univerzitet Utrecht 2014. ISBN: 978-90-393-6174-0.
28. Hren NI: Osteoporosis and mandibles. *Dentomaxillofacial Radiology* 2006; 35(3):178-84. DOI: 10.1259/dmfr/79749065.
29. Postić S: Osteopenične i osteoporotične promene u segmentima mandibula. Zadužbina Andrejević, Beograd, 2000.ž
30. Ilić DV, Stojanović S Lj: Application of Digital Radiography for Measuring in Clinical Dental Practice. *Srp Arh Celok Lek* 2015;1-2:16-22.
31. Antonijević Dj, Ilić DV, Medic V, Dodic SM, Obradovic-Djuricic K: Evaluation of conventional and digital radiography capacities for distinguishing dental materials on radiograms depending on the present radiopacifying agent. *Vojnosanit Pregled* 2014;71,11:1006-12
32. Bussabarger RS, Freeman S, Ivy AC: The experimental production of severe homogenous osteoporosis by gastrectomy in puppies. *Am J Physiol* 1938; 121: 137.
33. Detenbeck LC, Jousey J: Normal aging in the bone of the adult dog. *Clin Orthop* 1969; 65:76.
34. Goddard KM, Williams GD, Newberne PM et al: A comparison for all-meat, semi-moist and dry-type dog foods as diets for growing beagles. *J Am Vet Med Assoc* 1970; 157:1233.
35. Namba T, Ichii O, Nakamura T, Masum MA, Otani Y, Otsuka-Kanazawa S, Hosny Ali Elewa Y, Kon Y: Altered morpho-functional features of bones in autoimmune disease-prone BXSb/MpJ- Yaa mice. *Exp Biol Med* (Maywood). 2019. doi:10.1177/1535370219832810

36. Coates DB, Dixon RM, Murray RM, Mayer RJ, Miller CP, Kirgberger RM: Bone mineral density in the tail-bones of cattle: effect of dietary phosphorus status, live, weight, age and physiological status. *Animal Production Science* 2016; 58(5): 801-810. doi.org/10.1071/AN16376.
37. Writing Group for the ISCD Position Development Conference. Indications and reporting for dual-energy x-ray absorptiometry. *J Clin Densitom* 2004; 7:1:37–44.

MERENJE GUSTINE KOŠTANOG TKIVA MANDIBULE KOD PASA PRIMENOM DIGITALNE RADIOGRAFIJE

ILIĆ Dragan, STOJANOVIĆ Ljiljana, ANTONIJEVIĆ Djordje,
MILUTINOVIĆ-SMILJANIĆ Sanja, SAVIĆ-STANKOVIĆ Tatjana,
MILOSAVLJEVIĆ Željko

Radiološka dijagnostika služi kao jedna od osnovnih tehnika praćenja stadijuma bolesti u veterinarskoj medicini. Najnoviji podaci iz literature govore o prednostima digitalne radiologije/radioviografije (RVG) inspirisao je autore da predstave njenu moguću primenu u kliničkoj veterinarskoj stomatologiji. Digitalna radiografija korišćena u ovom istraživanju ostvarena je upotrebom uređaja RVG Trophy Radiologie SA 2001 opremljenog moćnim programom za linearna merenja (očitanja), denzitometriju, doterivanje kontrasta na radiogramu, trodimenzionalnu manipulaciju slike, uveličavanje detalja i njegovo orijentisanje. Cilj studije bio je da se proceni gustina koštane mase alveolarnog dela donje vilice kod sedam jorkširskih terijera. Merenje kostne gustine urađeno je na centralnim donjim sekutićima konverzijom jedinica sivobebe skale u ekvivalentnu debljinu aluminijuma (mm Al). Prosečna vrednost gustine kosti bila je u opsegu od 4,31 - 6,20 mm Al bez značajne statističke razlike između levog i desnog sekutića ($p > 0,01$). Naši rezultati su pokazali da je kombinacija RVG i aluminijumskog etalona pouzdano način za merenje gustine koštanog tkiva oko donjih centralnih sekutića pasa. Ovaj se metod može smatrati pogodnim za svakodnevnu upotrebu u kliničkoj veterinarskoj praksi.