

**STUDY OF THE DISTRIBUTION OF CD₃-T LYMPHOCYTES IN CAECA OF CHICKENS
EXPERIMENTALLY INFECTED WITH *EIMERIA TENELLA***

ILIĆ TAMARA, KNEŽEVIĆ MILJANA, DIMITRIJEVIĆ SANDA, NEŠIĆ V and
ALEKSIĆ-KOVAČEVIĆ SANJA

Faculty of Veterinary Medicine Belgrade

(Received 26. April, 2003)

*An immunohistochemical study of caecum tissue samples was performed on chickens that had been infected with *E. tenella* when 14 days old. Using antibodies of rabbits against T-CD₃ lymphocytes (DAKO EPOS N^oU 0026) and applying the direct peroxidase method, CD₃ positive lymphocytes in caeca were marked. This lymphocyte subpopulation, was localized in the lamina epithelial mucosa of the caecum. Increased immunoreactivity in the lamina epithelial mucosa of the caecum and stroma of the lamina propria mucosa, was observed already on the first day after infection with *E. tenella*, with the greatest intensity occurring between the third and fifth day. These findings demonstrate the existence of an early immunological response to infection caused by *E. tenella*, that is cell mediated, which is one of its most important characteristics.*

*Key words: chickens, coccidiosis, *E. tenella*, immunohistochemistry*

INTRODUCTION

Lymph tissue of the intestine consists of two types of formations, which are different, both structurally and functionally. The first types of lymph formation consists of single lymphocytes diffusely distributed in the epithelium and the lamina propria of the intestinal mucosa (Lillehoj and Chung 1992). The second type of lymph formation consists of lymphocytes clustered in nodes i.e. mucosal follicles (noduli lymphatici) in the intestine membrane. Lymph nodes in the intestinal wall appear separately (noduli lymphatici solitarii) or in groups of several together (noduli lymphatici aggregati) that form Peyers patches and are localized in the villi fur and submucosa (Lillehoj and Trout 1996).

The lymphocyte population of the intestinal mucosa of chickens is located in two places. The first matrix is found in the intraepithelial region of the intestine, labeled as intraepithelial lymphocytes (IEL). The second group consists of lymphocytes localized inside the fur and called lymphocytes of the lamina propria (LLP) (Arnaud-Battandier *et al.* 1980).

The entry of infectious types of Coccidia is connected with the mucosal regions of the caecum rich with lymphocyte tissue, covered by the epithelium (lym-

phoepithel), with a small number of entero-absorbent cells and a large number of intra-epithelial lymphocytes. Although the phenotype of these lymphocytes is similar to the phenotype of T cells on peripheral blood, intra-epithelial T lymphocytes are TCR gamma-delta and most of them release cytokines (IFN-gamma and IL-5) (Knežević *et al.* 1998).

IEL of birds are a heterogeneous cell population that includes of B and T lymphocytes and NK cells (Lillehoj and Chung 1992), but T lymphocytes predominate. Most of them carry surface CD₈ antigen receptors, which means that they are cytotoxic lymphocytes that can have an important role in resistance to secondary infections (Crago and Tomasi 1988). IEL show certain NK-activity, characteristic of the intestinal mucosa of mammals and birds and it is more distinct in this lymphocyte population than in lymphocytes of the lamina propria (Lillehoj and Trout 1993). In infections caused by *Eimeria* it was demonstrated that NK activity of IEL was of low intensity, but was still greater in than the NK activity of uninfected chickens, which indicates that NK cells can contribute to parasite elimination (Heyworth 1988). NK cell activity increases considerably against *Coccidia* in the presence of cytokines, pointing out the important involvement of T-lymphocytes in enhancing of the stimulating effects of NK cells on other cell populations. More specifically, IEL play a very important role in local defense of intestinal mucosa against coccidian invasion (Lillehoj and Bacon 1991; Dimitrijević *et al.* 1992). A certain number of IEL in chickens were CD₃⁺ and were detected as early as six days after hatching (Rothwell *et al.* 1995).

Detailed immunohistochemical analysis of the intestinal tissue has shown that CD₃ lymphocytes are localized in the lamina propria and the epithelium with a somewhat larger number in the epithelium. TCR₁⁺ cells are primarily located in the epithelium. On the other hand, TCR₂⁺ cells are located mainly in the lamina propria mucosa, and a minimal number can be found in the epithelium (Bucy *et al.* 1988).

None of the above mentioned subsets were found in the intestinal mucosa of just hatched chickens and only occasionally were TCR₁⁺ and TCR₂⁺ cells visible in the intestine of three day old chickens. On the sixth day after hatching both subsets are present, with TCR₁⁺ cells dominant in the epithelium. TCR₂⁺ cells were very early detected in the lamina propria mucosa (Rothwell *et al.* 1995).

MATERIALS AND METHODS

1. *Animals.* This study was performed on a total of a 100 one day old broilers, type "Hybro". After a preparation period of 14 days, the broilers were divided into two subgroups of 20 and 80 birds. Subgroup Ia was the control group, while subgroup Ib, was inoculated at 14 days old with the *E. tenella* culture. With a plastic probe directly placed into the crop 2ml inoculate containing 4 x 10⁵ sporulated oocysts of *E. tenella* was administered. A field type of *E. tenella* isolated from the caeca of diseased poultry with prominent clinical symptoms was used.

In the subsequent seven days after infection chicken health was monitored, as well as the clinical state and the mortality dynamics of all animals in the study. In the *E. tenella* infected subgroup, five birds were killed daily and a detailed pathoa-

anatomical examination made from the second to the seventh day after infection, that is from the sixteenth to the twenty-first day of the experiment.

2. *Specimen preparation.* Tissue samples of caecum were taken for immunohistochemical testing, after fixation in 99.9% methanol, dehydration in a series of alcohol rinses, clearance in xylol and insertion in paraffin. The paraffin embedded sections 3-5 µm thick were immunohistochemically treated.

3. *Immunohistochemistry.* Using the immunohistochemical direct peroxidase method CD₃-T lymphocytes in caeca of infected and control chickens were marked, kit with antibodies of rabbits against human T-CD₃ lymphocytes.

Tissue samples 3-5 µm thick, were fixed in 99.9% methanol (48h), processed in xylol (2x15min), then hydrated in a series of alcohol dilutions (100%, 96%, 70% and 50%) and rinsed in distilled water. After being blocked in endogenous peroxidase (in 3% H₂O₂-5 min), the samples were rinsed in TBS (Tris Buffered Saline, pH=7.5) for 3x5min, and then anti-CD₃ antibodies were applied (Anti CD₃/HRP) for 60min, at room temperature, followed by rinsing with TBS for 3x5 min. The control samples were treated with TBS alone.

The reaction was visualized possible with a 0.05% DAB-H₂O₂ solution in 0.1M imidazole-HCl (pH=7.1) for 10min, and haematoxylin used for contrast staining.

Lastly, the samples were covered in Canada balsam and prepared for microscopy.

RESULTS

The CD₃-T lymphocyte set was labeled by using a commercial marker for human T lymphocytes, and CD₃ expression was established as a finely granulated brown precipitant on the membranes and the T lymphocyte cytoplasm. The differences in distribution of the cells thus marked depended on the day of infection.

On the second day after infection immunoreactive cells in the caeca of the chickens were for the most part intraepithelially localized, in the surface epithelium as well as in the epithelium of Lieberkuhn crypts. Rare, single, diffusely spread marked cells were noticed in the stroma (Figure 1). This T cell population was not observed in some locations of the lamina propria mucosa

On the third day after infection there was a considerable increase in marked cells, localized in the epithelium of villi and Lieberkuhn crypts in the caeca of the chickens, and occasionally in the stroma of the lamina propria mucosa. The greatest concentration of immunoreactive cells was observed in the epithelial cells of the lamina epithelialis.

On the fourth day after infection the CD₃-T lymphocyte subset of cells was found diffusely distributed in the epithelium of the Lieberkuhn crypts in the caeca of the infected chickens. In the surface epithelium the immunoreactive cells were rare or absent. In this stage of the infection the marked cells were almost evenly distributed in the epithelium and the stroma of the lamina propria mucosa. Their presence in this area of caecal tissue was more intense than on the previous day.

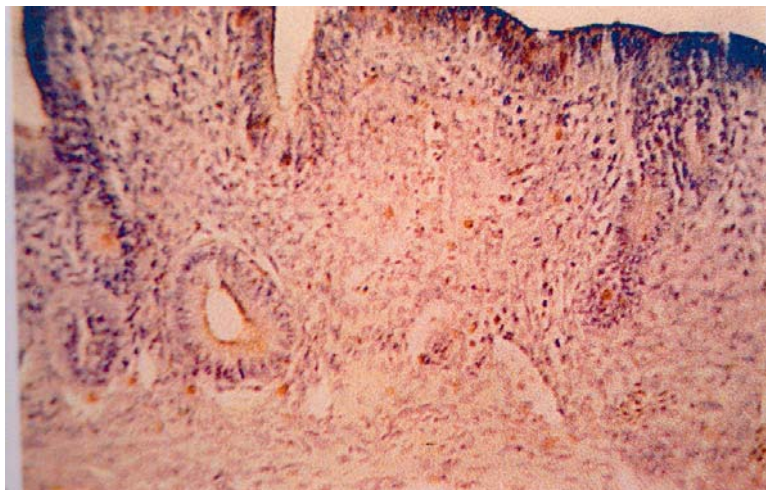


Figure 1. Chicken caecum, 2nd days after infection showing expression of CD₃, DP, 20X

An increased number of immunoreactive cells was observed, in the caeca of the experiment animals, on the fifth day after infection. They were organized as a diffused infiltrate and were localized intraepithelially (only at the bottom of Lieberkuhn crypts), because the surface epithelium was already completely necrotic (Figure 2). In some of the Lieberkuhn crypts the immunoreactive cells were grouped in clusters, most prominently in those glands whose lumen was completely closed, as a result of the intensive multiplication of their cells.

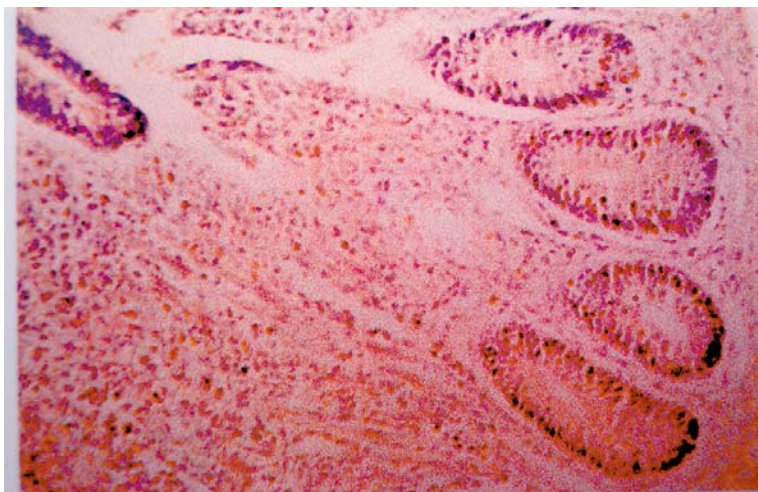


Figure 2. Chicken caecum, 5th days after infection showing expression of CD₃, DP, 20X

On the sixth day after infection, a reduced number of marked cells was observed in the caeca of the infected animals compared to the previous days. The diffuse infiltrate, mostly made up of immunoreactive lymphocytes, was localized intraepithelially. In certain areas of the stroma the marked cells were partly distributed in a smaller number, while in other areas there were CD₃ lymphocyte clusters. In the preserved areas of the surface epithelium an immunoreactive cell subpopulation was also observed in the form of unevenly distributed cells that were rare in the mentioned location.

On the seventh day of infection in the caeca of the chickens the number of immunoreactive cells was further decreased. They were mostly located in the epithelium of the Lieberkuhn crypts (because the surface epithelium was completely damaged), and an occasional, diffusely distributed cell was observed in the stroma.

DISCUSSION

The focus of this study was directed towards examining the immunological cell response in the caeca of chickens artificially infected with *E. tenella*. In relation to this, the behavior of the CD₃-T lymphocyte subpopulation after artificial infection with *E. tenella* was monitored, as a certain number of intraepithelial lymphocytes of chickens is CD₃+ and can be detected on the sixth day after hatching. It is assumed that they play a significant role in the protection against *Coccidia* as they perform an important function in stabilizing the antigen receptor and transduction of the activation signal through the membrane and in the inside of the cell.

Our findings in the caeca of experimental chickens, support this possibility. Thus on the second day after infection, the intraepithelial localized CD₃-T lymphocytes showed a somewhat stronger immunoreactivity in comparison with the control group. CD₃+ lymphocytes were present in the lamina propria mucosa as well, although only individually. This results are in accordance with the findings of Bucy *et al.* (1988), that also noted a slightly larger presence of the CD₃-T lymphocyte subset in the lamina epithelialis of the caecum.

In the caeca of the experimentally infected chickens the number of immunoreactive cells gradually increased. As a result, on the third day after infection they were detected not only in the surface epithelium, but also in the deeper layers of the Lieberkuhn crypts. There was an occasional increase in the number of positive cells in the stroma of the lamina propria mucosa. On the fourth day after infection, CD₃ cells were diffusely distributed in the epithelium of the Lieberkuhn crypts, while in the surface epithelium they were not detected, which is most likely a result of the intensive necrosis of the lamina epithelialis of the caecum. A somewhat larger immunoreaction in these animals was observed in the stroma of the lamina propria mucosa. On the fifth day after infection the a predominant finding in the caeca was immunoreactive cells in the form of a diffuse infiltrate in the lamina propria mucosa. CD₃+ cells were seen only in the epithelial bottom of the Lieberkuhn crypts, because the surface epithelium was completely necrotic.

Thus, the number of immunoreactive cells in caeca increased during the development of the infection reaching a maximum between the third and fifth day af-

ter infection. These results are in accordance with the reports of Bucy *et al.* (1988), Rothwell *et al.* (1995) and Sharma (1997), who investigated the CD₄ and CD₈ lymphocyte subpopulations as well as CD₃. They claimed that the CD₄⁺ lymphocytes are localized completely in the lamina epithelialis, while the CD₈ lymphocytes have a similar localization as the CD₃ cells i.e. are found at the same time in the lamina epithelialis and the lamina propria mucosa.

However, on the sixth and seventh day after infection, immunoreactive cells were not observed in the epithelial layer in the caeca of the experimentally infected animals, rather they were present only as a diffuse infiltrate placed subepithelially. This finding confirms the results of Rothwell *et al.* (1995), which, in the same period, showed a decrease of immunoreactivity for the CD₃. The partly established immunoreactivity of the lamina epithelialis in this stage of infection corresponds to the findings in the control animals.

The evidence for the immunoreactivity of the caecal tissue confirms the existence of an early immunological response to infection caused by *E. tenella*, which is cellular in character and has a major role in the defense of the host against this causative agent.

Address for correspondence:
 Mr Tamara Ilić,
 Faculty of Veterinary Medicine,
 University of Belgrade,
 Bulevar JNA 18,
 11000 Belgrade, Serbia & Montenegro

REFERENCES:

1. Arnaud-Battandier MD, Lawrence EC, Blaese RM, 1980, Lymphoid populations of gut mucosa in chickens, *Dig Dis Sci*, 25, 252-9.
2. Bucy RP, Chen LC, Cihak J, Losch U, Cooper MD, 1988, Avian T cells expressing gamma delta receptors localize in the splenic sinusoids and the intestinal epithelium, *J Immunol*, 141,7, 2200-5.
3. Crago SS, Tomasi TB, 1988, Immunoglobulin circulation and secretion, In: Heyworth MF, Jones AL, *Immunology of the Gastrointestinal Tract and Liver*, (New York, Raven Press).
4. Dimitrijević Sanda, Pujić N, Čupić V, Savovski K, Dimitrijević B, 1992, Suppression of thymocyte proliferation by the coccidiostatic salinomycin and derivatives of penicillin, *Acta Veterinaria*, 42, 5-6, 291-8.
5. Heyworth MF, 1988, T-cells and other non-B lymphocytes, In: Heyworth MF, Jones AL, *Immunology of the Gastrointestinal Tract and Liver*, (New York, Raven Press).
6. Knežević Milijana, Aleksić-Kovačević Sanja, Božić Tatjana, Jovanović M, 1998, Light microscopic and immunohistochemical investigation of Peyer's patches in calves experimentally infected with rota virus, *Acta Veterinaria*, 48, 5-6, 331-8.
7. Lillehoj HS, Trout JM, 1996, Avian gut-associated lymphoid tissues and intestinal immune responses to *Eimeria* parasites, *Clin Microbiol Rev*, 9, 349-60.
8. Lillehoj HS, Trout JM, 1993, *Coccidia*: a review of recent advances on immunity and vaccine development, *Avian Pathol*, 22, 3-31.
9. Lillehoj HS, Chung KS, 1992, Postnatal development of T-lymphocyte subpopulations in the intestinal intraepithelium and lamina propria in chickens, *Vet Immunol Immunopathol*, 31, 347-60.
10. Lillehoj HS, Bacon LD, 1991, Increase of intestinal intraepithelial lymphocytes expressing CD8 antigen following challenge infection with *Eimeria acervulina*, *Avian Dis*, 35, 294-301.

11. Rothwell L, Gramzinski RA, Rose ME, Kaiser P, 1995, Avian coccidiosis: changes in intestinal lymphocyte populations associated with the development of immunity to *Eimeria maxima*, *Parasite Immunol*, 17,10, 525-33.
12. Sharma MJ, 1997, The structure and function of the avian immune system, Proc XI-th Intern Cong World Vet Poultry Assoc, Budapest, Hungary, 18-22, 229-30.

ISPITIVANJA DISTRIBUCIJE CD₃-T LIMFOCITA U CEKUMIMA PILIĆA EKSPERIMENTALNO INFICIRANIH SA EIMERIA TENELLA

ILIĆ TAMARA, KNEŽEVIĆ MILIJANA, DIMITRIJEVIĆ SANDA, NEŠIĆ V I
ALEKSIĆ-KOVAČEVIĆ SANJA

SADRŽAJ

Imunohistohemijska ispitivanja tkivnih isečaka cekuma, izvedena su kod pilića koji su 14. dana starosti inficirani sa *E. tenella*. Korišćenjem komercijalnih kit-antitela kunića protiv T-CD₃ limfocita i primenom metode direktne peroksidaze (DP), obeleženi su CD₃ pozitivni limfociti u cekumima. Navedena limfocitna subpopulacija detektovana CD₃ antitelom, lokalizovana je u lamina epithelialis mucosa cekuma. Pojačana imunoreaktivnost u lamina epithelialis mucosa cekuma i strome lamina propria mucosa, zapažena je već prvog dana posle infekcije, sa najvećim intenzitetom između 3. i 5. dana. Ovakvi nalazi dokazuju postojanje rano imunološkog odgovora na infekciju prouzrokovanu sa *E. tenella*, koji je ćelijskog karaktera, što predstavlja jedno od njegovih najvažnijih obeležja.